



**PATIENT**

Monty Simon

**PRESENTING CLINICAL SIGNS**

P has been painful when getting on and off furniture for the past 2 weeks. O thought it was over his right hip. P is still active and eating well. Temp: 102.8F (nervous in the clinic). No painful reaction to manipulation of the hips or palpation of the epaxial muscles.

**SPECIES**

Canine

Abnormal PE/Chem/CBC/UA Results: No lab work performed at this time.

**RADIOGRAPHIC STUDY OF THE PELVIS**

Radiographs of the pelvis in two orthogonal imaging planes.

**BREED**

Doberman Pincher

**RADIOGRAPHIC FINDINGS**

The last lumbar vertebra is counted as L7.

**SEX**

Neutered Male

The vertebral endplates L5/L6 to L7/S1 present moderate lateral spondylosis formation. Osseous spurs are superimposed on the ventral aspect of the neuroforamina L5/L6 and L6/L7.

Both coxofemoral joints present mild osteophyte new bone formation level with the transition between the femoral head & neck.

**AGE**

5 Years

**RADIOGRAPHIC DIAGNOSIS**

- Mild degenerative osteoarthritis coxofemoral joints bilaterally
- Spondylosis deformans L5/L6 to L7/S1

**INTERPRETED BY**

Sebastian Schaub, DVM  
Dr. med. vet. DipECVDI

**INTERPRETATION OF THE FINDINGS & FURTHER RECOMMENDATIONS**

The radiographic study presents no specific abnormalities, explaining the described clinical signs. The degenerative changes along the region of the lumbosacral junction might be associated with degenerative lumbosacral stenosis – cross-sectional imaging is warranted to rule in/out the diagnosis completely – as source for the clinical signs. Lateral spondylosis formation can be unilateral and if there is impingement of the respective nerve roots, being a cause for pain.

**HOSPITAL NAME**

Neighborhood Pet  
Health Center

The mild degenerative changes of the coxofemoral joints are likely incidental, as no pain was elicited by manipulation of the coxofemoral joints.

**REFERRING VET**

Daniel Finch

**INVOICE**

49342

**DATE**

1-5-22



**PATIENT**

Monty Simon

**SPECIES**

Canine

**BREED**

Doberman Pincher

**SEX**

Neutered Male

**AGE**

5 Years

**INTERPRETED BY**

Sebastian Schaub, DVM  
Dr. med. vet. DipECVDI

**HOSPITAL NAME**

Neighborhood Pet  
Health Center

**REFERRING VET**

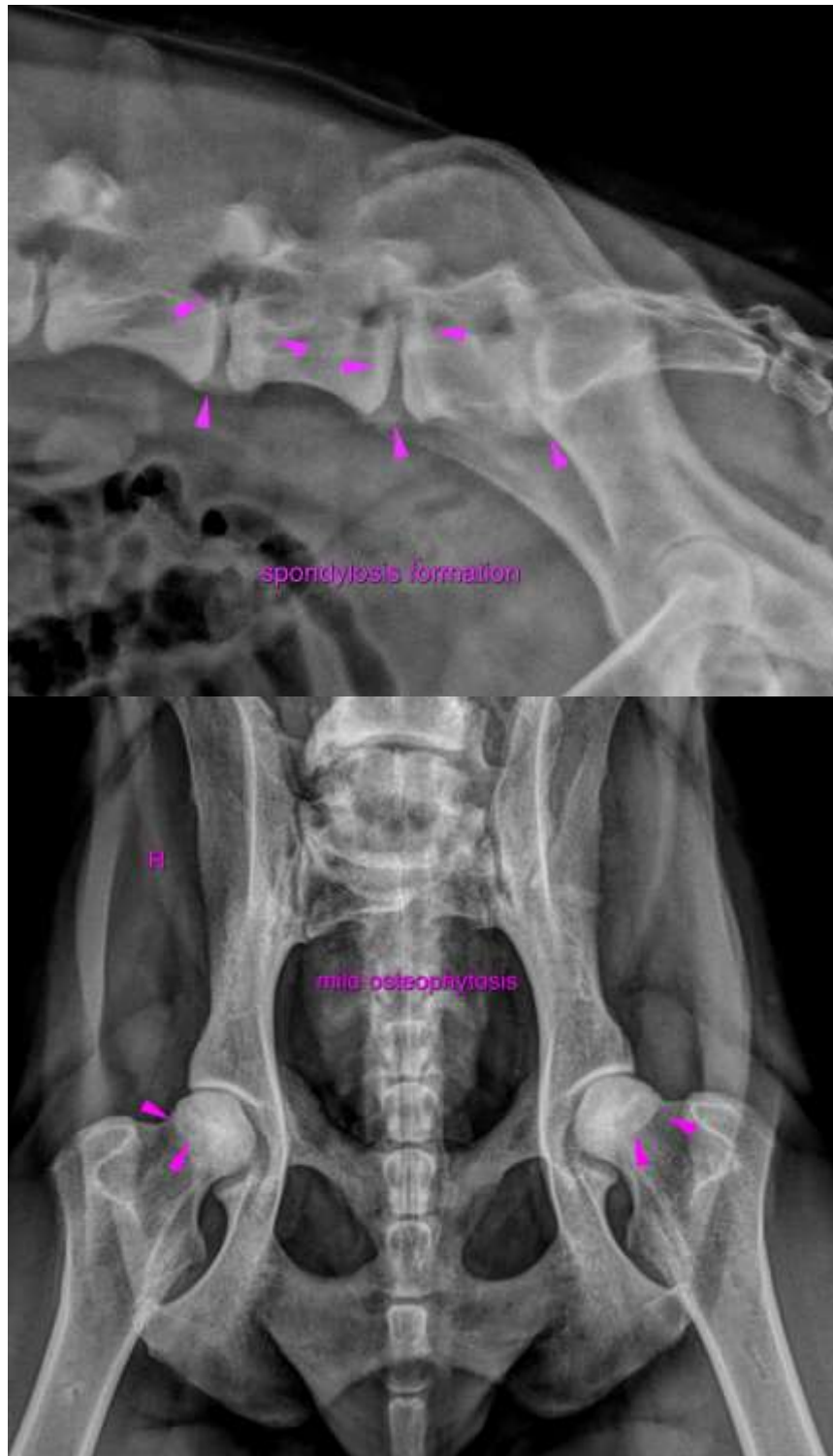
Daniel Finch

**INVOICE**

49342

**DATE**

1-5-22





**PATIENT**

Monty Simon

**SPECIES**

Canine

**BREED**

Doberman Pincher

**SEX**

Neutered Male

**AGE**

5 Years

**INTERPRETED BY**

Sebastian Schaub, DVM  
Dr. med. vet. DipECVDI

**HOSPITAL NAME**

Neighborhood Pet  
Health Center

**REFERRING VET**

Daniel Finch

**INVOICE**

49342

**DATE**

1-5-22

The information and recommendations provided are based on the images presented by the referring veterinarian. No evaluation can be communicated regarding pathology that was not visible in the image/video clips provided.

Thank you for this referral. If the clinical or image interpretation does not parallel your findings or if I can be of any further assistance please contact me.

**Sebastian Schaub**, Sebastian Schaub, DVM, Dr. med. vet. DipECVDI  
sebast.schaub@gmail.com