



PATIENT

Babae Kovtanuka

PRESENTING CLINICAL SIGNS

Femoral fracture repaired in November, presented yesterday for non ambulatory/painful, discovered fracture of L4 - suspect all due to underlying osteopenia secondary to nutritional hyperparathyroidism

SPECIES

Feline

COMPUTED TOMOGRAPHY OF THE ENTIRE SPINE & HIND LIMBS

A pre- and post-contrast CT study of the entire spine and the hind limbs in a bone and soft tissue reconstruction are provided for review.

BREED

Domestic Shorthair

COMPUTED TOMOGRAPHIC FINDINGS

The osseous structures present generalized moderate decreased density of the osseous structures of the axial and appendicular skeleton. The vertebral bodies present a coarse trabecular pattern, and the cortices of the long bones are thin.

SEX

M

The vertebral body of L4 presents with a short oblique fracture of the caudal metaphysis with mild ventral displacement of the caudal vertebral endplate and step formation of the vertebral canal. The fracture gap is completely filled with trabecular bone.

AGE

6 Months

No additional abnormalities are seen along the cervical, thoracic & lumbar spine.

INTERPRETED BY

Sebastian Schaub, DVM
Dr. med. vet. DipECVDI

A surgical plate and an intramedullary pin are seen extending from the greater trochanter along the lateral surface of the right femur up to the level of the distal third of the femoral diaphysis. Multiple beam hardening artefacts are emanating from the surgical implant. Mild callus formation is seen at the medial aspect of the proximal third of the right femoral diaphysis. The fracture cannot be appreciated.

COMPUTED TOMOGRAPHIC DIAGNOSIS

- Generalized osteopenia
- Chronic mildly displaced short oblique fracture caudal segment of vertebral body of L4 – the fracture is in the remodeling phase
- Current state post right sided femoral diaphyseal fracture repair – the fracture is in the remodeling phase.

HOSPITAL NAME

Animal Health Partners

REFERRING VET

Lea Mehrkens

INTERPRETATION OF THE FINDINGS & FURTHER RECOMMENDATIONS

Regarding the history nutritional hyperparathyroidism is suspect as underlying cause for the generalized osteopenia – predisposing the pathological fracture. Osteogenesis imperfecta – inherited type I collagen defect – can result in osteopenia and increased fragility of the osseous structures as well.

INVOICE

49346

The fracture of the vertebral body of L4 appears to be chronic and the fracture gap is already filled with trabecular bone. I suspect that the fracture might have occurred together with the femoral fracture.

DATE

1-5-22

No additional abnormality is appreciated, explaining the acute clinical signs. An MRI study of the spine might be used as advanced imaging tool to screen for compressive myelopathy, ischemic insult, other.



PATIENT

Babae Kovtanuka

SPECIES

Feline

BREED

Domestic Shorthair

SEX

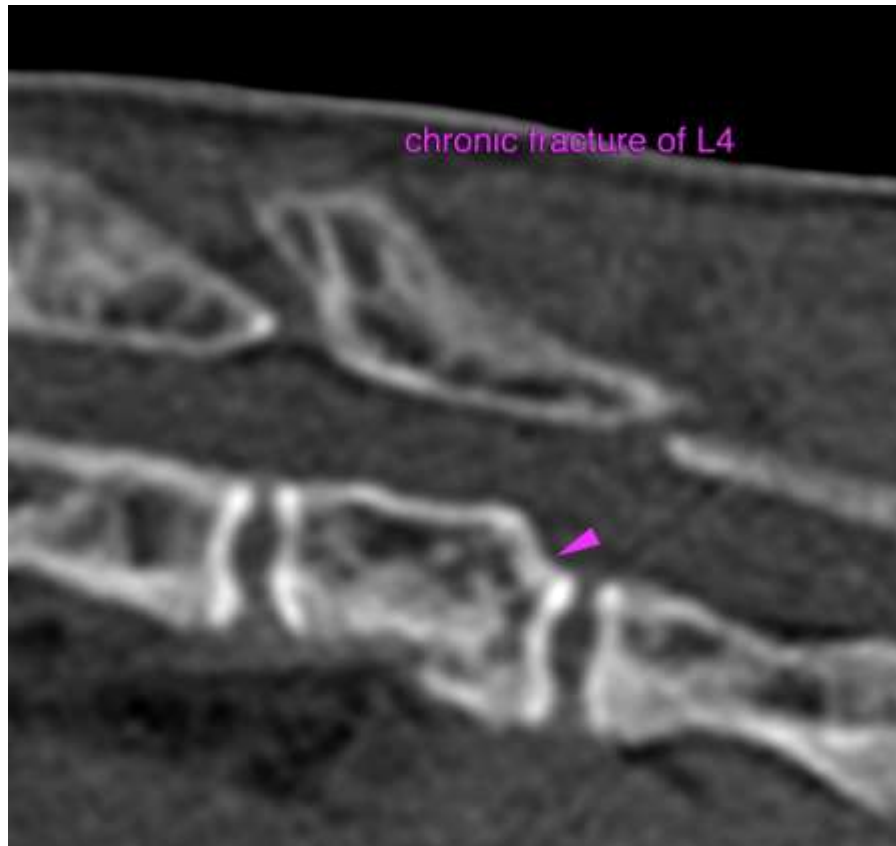
M

AGE

6 Months

INTERPRETED BY

Sebastian Schaub, DVM
Dr. med. vet. DipECVDI



HOSPITAL NAME

Animal Health
Partners

REFERRING VET

Lea Mehrkens

INVOICE

49346

DATE

1-5-22

The information and recommendations provided are based on the images presented by the referring veterinarian. No evaluation can be communicated regarding pathology that was not visible in the image/video clips provided.

Thank you for this referral. If the clinical or image interpretation does not parallel your findings or if I can be of any further assistance please contact me.

Sebastian Schaub, Sebastian Schaub, DVM, Dr. med. vet. DipECVDI
sebast.schaub@gmail.com