



**PATIENT**

Phoebe Kupka

**PRESENTING CLINICAL SIGNS**

This animal has splenic nodules consistent with lymphoid nodules and now anorexia. Progressive weight loss.

**SPECIES**

Canine

**RADIOGRAPHIC STUDY OF THE THORAX**

Radiographs of the thorax in three imaging planes are provided for review.

**BREED**

Great Pyrenees Mix

**RADIOGRAPHIC FINDINGS**

The surrounding bony structures are within normal limits.

The extrathoracic soft tissues present homogeneous without abnormalities.

The heart is of normal size and shape, there is no evidence of cardiac chamber or vascular enlargement. The pulmonary vasculature is within normal limits.

**SEX**

Spayed Female

The cranial mediastinum presents the expected soft tissue opacity. The mediastinal width is less than twice the width of the vertebral column at the same level.

**AGE**

12 Years, 10 Months

The trachea is normal in diameter and presents the anticipated course. The luminal outline of the trachea is smooth.

The bronchial tree presents with thin walls and tapers uniformly towards the periphery as expected.

**INTERPRETED BY**

Sebastian Schaub, DVM  
Dr. med. vet. DipECVDI

The thin walled gas filled lesions appreciated in the previous radiographic study are less well visible in the current set of radiographs. The remainder of the lung parenchyma presents the expected architecture and opacity; the intrapulmonary vascular branching is seen up to the third order lung vessels.

**HOSPITAL NAME**

All Pets Medical  
Center

The diaphragm is well delineated with even surface and the expected mild cranial bulging of the diaphragmatic cupola.

**RADIOGRAPHIC DIAGNOSIS**

- History of bullae

**REFERRING VET**

J. Jill Heatley, DVM

**INTERPRETATION OF THE FINDINGS & FURTHER RECOMMENDATIONS**

The radiographic study of the thorax presents without clinically relevant abnormalities, but the known bullae.

**INVOICE**

56004

**DATE**

1-4-23



**PATIENT**

Phoebe Kupka

**SPECIES**

Canine

**BREED**

Great Pyrenees Mix

**SEX**

Spayed Female

**AGE**

12 Years, 10 Months

**INTERPRETED BY**

Sebastian Schaub, DVM  
Dr. med. vet. DipECVDI

**HOSPITAL NAME**

All Pets Medical  
Center

**REFERRING VET**

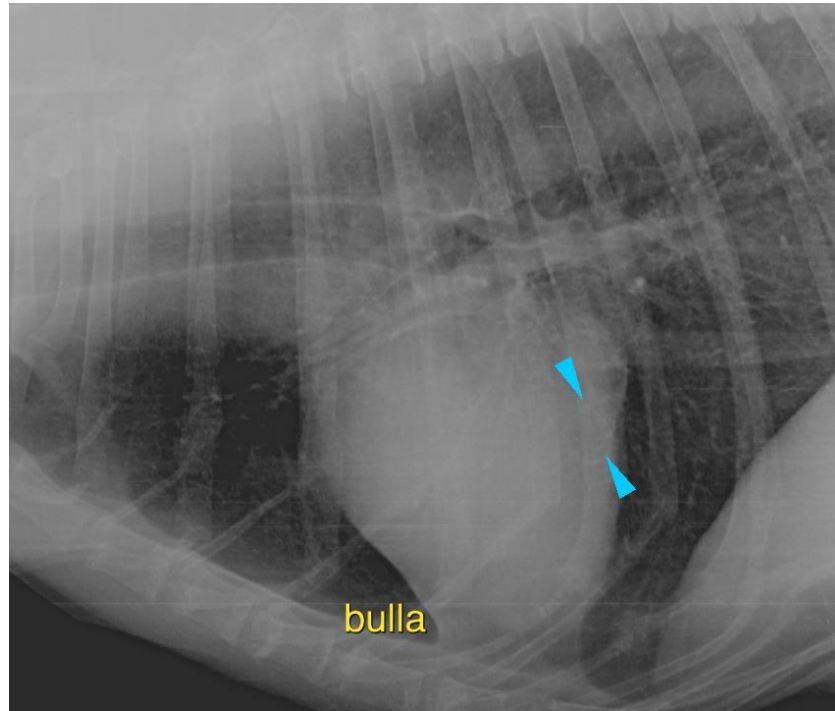
J. Jill Heatley, DVM

**INVOICE**

56004

**DATE**

1-4-23



**The information and recommendations provided are based on the images presented by the referring veterinarian/sonographer. No evaluation can be communicated regarding pathology that was not visible in the image/video clips provided.**

Thank you for this referral. If the clinical or image interpretation does not parallel your findings or if I can be of any further assistance please contact me.

**Sebastian Schaub**, Sebastian Schaub, DVM, Dr. med. vet. DipECVDI  
sebast.schaub@gmail.com