



PATIENT

Luna (Kitty) Guay

PRESENTING CLINICAL SIGNS

Lethargic
Abnormal PE/Chem/CBC/UA Results: mildly elevated ALT, rest WNL

SPECIES

Feline

RADIOGRAPHIC STUDY OF THE ABDOMEN

Radiographs of the abdomen in three imaging planes are provided for review.

BREED

Domestic Shorthair

RADIOGRAPHIC FINDINGS

The surrounding bony structures are within normal limits.

No abnormalities of the extraabdominal soft tissues are noted. The abdominal wall is smooth and thin.

SEX

Female spayed

The serosal detail is maintained throughout the peritoneal and retroperitoneal space.

The hepatic volume is generalized increased, and the margins present an irregular convex shape. A soft tissue opaque mass is protruding from the mid division of the liver, presenting convex shaped caudal margins. The gastric axis is deviated caudally.

AGE

7 Years

The splenic head is in the anticipated position and within normal limits for size and opacity.

Both kidneys are seen and present with normal size, shape, delineation and opacity. The urinary bladder is in its anticipated position. No radiopaque calculi are noted throughout the upper and lower urinary tract.

INTERPRETED BY

Sebastian Schaub, DVM
Dr. med. vet. DipECVDI

The stomach is in its anticipated position and presents normal content.

The small intestinal loops are of even diameter and non-dilated, a small amount of gas is seen within the small intestinal loops and considered within normal limits.

HOSPITAL NAME

St. Catherine's Animal Hospital

The colon is seen in the expected position and presents with appropriate content.

RADIOGRAPHIC DIAGNOSIS

- Hepatic nodular enlargement

REFERRING VET

Dr. Jui Gokhale

INTERPRETATION OF THE FINDINGS & FURTHER RECOMMENDATIONS

The enlarged liver with the rounded margins is concerning for hepatic neoplastic transformation (e.g. carcinoma, round cell tumor). Differentials can include hepatic cysts, regeneration nodule, chronic hepatitis. Ultrasound ± FNA sampling can be used for further workup.

INVOICE

55988

DATE

1-4-23



PATIENT

Luna (Kitty) Guay

SPECIES

Feline

BREED

Domestic Shorthair

SEX

Female spayed

AGE

7 Years

INTERPRETED BY

Sebastian Schaub, DVM
Dr. med. vet. DipECVDI

HOSPITAL NAME

St. Catherine's Animal
Hospital

REFERRING VET

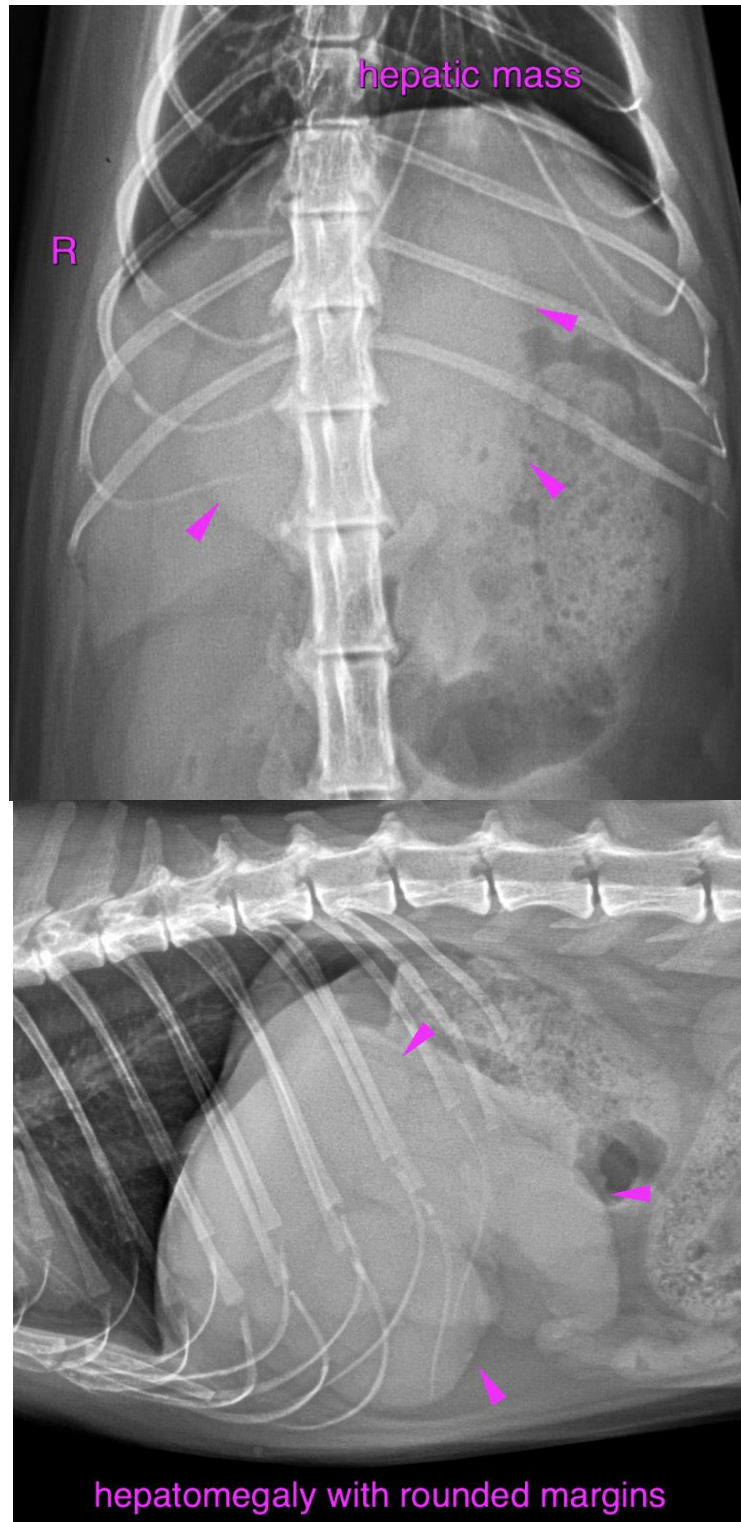
Dr. Jui Gokhale

INVOICE

55988

DATE

1-4-23





PATIENT

Luna (Kitty) Guay

SPECIES

Feline

The information and recommendations provided are based on the images presented by the referring veterinarian/sonographer. No evaluation can be communicated regarding pathology that was not visible in the image/video clips provided.

BREED

Domestic Shorthair

Thank you for this referral. If the clinical or image interpretation does not parallel your findings or if I can be of any further assistance please contact me.

Sebastian Schaub, Sebastian Schaub, DVM, Dr. med. vet. DipECVDI
sebast.schaub@gmail.com

SEX

Female spayed

AGE

7 Years

INTERPRETED BY

Sebastian Schaub, DVM
Dr. med. vet. DipECVDI

HOSPITAL NAME

St. Catherine's Animal
Hospital

REFERRING VET

Dr. Jui Gokhale

INVOICE

55988

DATE

1-4-23