

**PATIENT**Katana Aguilar  
Cabrera**PRESENTING CLINICAL SIGNS**

limping both hind legs

**SPECIES**

Canine

**RADIOGRAPHIC STUDY OF THE PELVIS AND STIFLE JOINTS**

A complete set of radiographs of the pelvis and stifle joints is provided for review. Radiographs are provided in JPEG file format.

**BREED**

Cane Corso

**RADIOGRAPHIC FINDINGS**

The spinous process of S1 is not fused with the spinous process of S2. The osseous and surrounding soft tissue structures of the pelvis are within normal limits. The coxofemoral joints present smooth osseous margins and mild incongruity of the joint space – with mild widening medially.

**SEX**

F

The left stifle joint presents evidence of moderate intracapsular soft tissue swelling, effacing the infrapatellar fat pad, and distorting the fascial plane caudally. There is overexposure/limited contrast (JPEG file format) of the soft tissues cranial aspect of the stifle joint, there appears to be a mild intracapsular soft tissue swelling. Both stifle joints present mild pointed margins distal aspect of the patella and proximal aspect of the femoral trochlear ridge.

**AGE**

15 Months

**RADIOGRAPHIC DIAGNOSIS**

- Moderate articular swelling left stifle joint
- Mild articular swelling right stifle joint
- Transitional form of hip dysplasia - incidental
- Lumbosacral transitional vertebra type I

**INTERPRETED BY**Sebastian Schaub, DVM  
Dr. med. vet. DipECVDI**INTERPRETATION OF THE FINDINGS & FURTHER RECOMMENDATIONS****HOSPITAL NAME**The Collegeway  
Animal Hospital

The articular swelling of both stifle joints can be traumatic, degenerative or inflammatory in origin. The most common cause would be pathology of the cranial cruciate ligament ± meniscal pathology. However, as there is bilateral swelling and without or only very mild degenerative changes, a synovial tap is beneficial to rule out underlying polyarthritis – check if there is swelling of other joints as well.

**REFERRING VET**

Dr. Ehab Hanna

**INVOICE**

49292

**DATE**

1-4-22



**PATIENT**

Katana Aguilar  
Cabrera

**SPECIES**

Canine

**BREED**

Cane Corso

**SEX**

F

**AGE**

15 Months

**INTERPRETED BY**

Sebastian Schaub, DVM  
Dr. med. vet. DipECVDI

**HOSPITAL NAME**

The Collegeway  
Animal Hospital

**REFERRING VET**

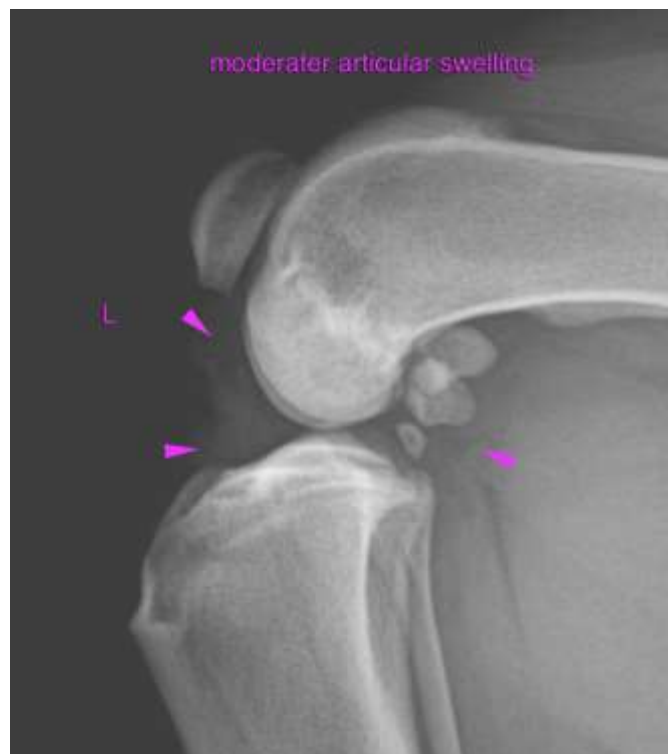
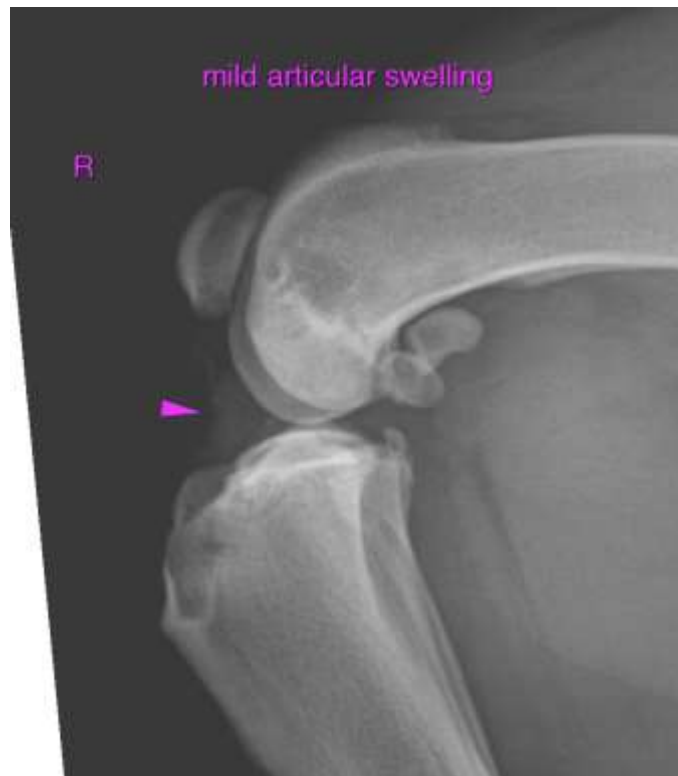Dr. Ehab Hanna

**INVOICE**

49292

**DATE**

1-4-22





**PATIENT**

Katana Aguilar  
Cabrera

The information and recommendations provided are based on the images presented by the referring veterinarian. No evaluation can be communicated regarding pathology that was not visible in the image/video clips provided.

**SPECIES**

Canine

Thank you for this referral. If the clinical or image interpretation does not parallel your findings or if I can be of any further assistance please contact me.

**BREED**

Cane Corso

**Sebastian Schaub**, Sebastian Schaub, DVM, Dr. med. vet. DipECVDI  
sebast.schaub@gmail.com

**SEX**

F

**AGE**

15 Months

**INTERPRETED BY**

Sebastian Schaub, DVM  
Dr. med. vet. DipECVDI

**HOSPITAL NAME**

The Collegeway  
Animal Hospital

**REFERRING VET**

Dr. Ehab Hanna

**INVOICE**

49292

**DATE**

1-4-22