

**PATIENT**

Fantuz Gingerich

**PRESENTING CLINICAL SIGNS**

History of being found outside acutely lame on the right pelvic limb 12/29/21. Radiographs performed during the visit were consistent with a closed, comminuted fracture of the right proximal femur. The patient was medically boarded at their primary veterinarian receiving pain medications and care until they were able to have a surgical consultation with us. During the consultation we did a CT scan of the leg.

**SPECIES**

Feline

**COMPUTED TOMOGRAPHY OF THE RIGHT HIND LIMB****BREED**

A high resolution plain CT study of the right hind limb is provided for review.

DSH

**COMPUTED TOMOGRAPHIC FINDINGS****SEX**

There is a mild oblique fracture in the mid diaphysis of the right femur with a fissure line extending distally up into the distal third of the mediocaudal cortex of the femur. The distal segment is displaced caudally, laterally and proximally. Multiple small cortical fragments are seen level with the fracture gap.

MN

**AGE**

The proximal third of the right femur presents moderate callus formation and multiple fissure lines are extending proximally up to the medial aspect of the femoral neck.

3 Years

The left iliac wing presents with a transverse non-displaced fracture, completely bridged by smooth callus formation.

**INTERPRETED BY**

Sebastian Schaub, DVM  
Dr. med. vet. DipECVDI

**COMPUTED TOMOGRAPHIC DIAGNOSIS**

- Right sided subacute to chronic closed mid diaphyseal short oblique femoral fracture with multiple fissure lines extending up to the level of the femoral neck
- Chronic traumatic non-displaced fracture left iliac wing – fracture is in the reparation phase

**HOSPITAL NAME**

Bluegrass Veterinary  
Specialists

**INTERPRETATION OF THE FINDINGS & FURTHER RECOMMENDATIONS**

Surgical fracture repair is the therapy of choice, be aware of the fissure lines.

**REFERRING VET**

Guevara

**INVOICE**

49295

**DATE**

1-4-22



**PATIENT**

Fantuz Gingerich

**SPECIES**

Feline

**BREED**

DSH

**SEX**

MN

**AGE**

3 Years

**INTERPRETED BY**

Sebastian Schaub, DVM  
Dr. med. vet. DipECVDI

**HOSPITAL NAME**

Bluegrass Veterinary  
Specialists

**REFERRING VET**

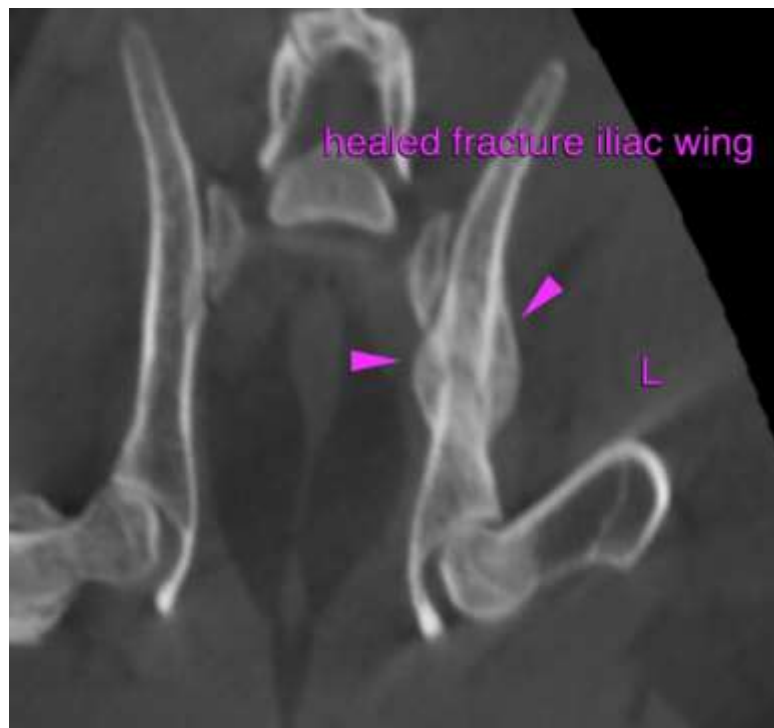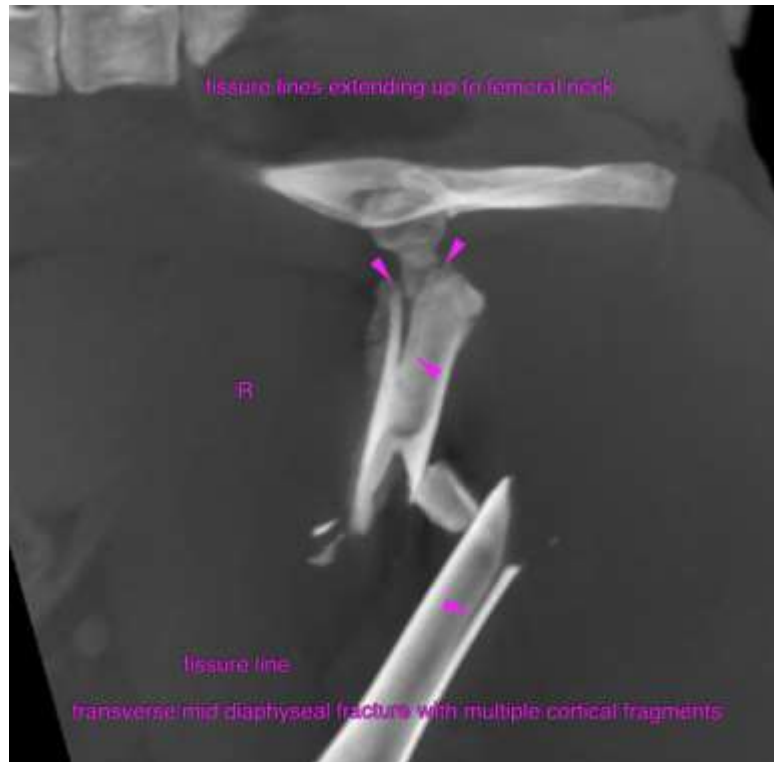
Guevara

**INVOICE**

49295

**DATE**

1-4-22





**PATIENT**

Fantuz Gingerich

**SPECIES**

Feline

The information and recommendations provided are based on the images presented by the referring veterinarian. No evaluation can be communicated regarding pathology that was not visible in the image/video clips provided.

**BREED**

DSH

Thank you for this referral. If the clinical or image interpretation does not parallel your findings or if I can be of any further assistance please contact me.

**SEX**

MN

**Sebastian Schaub**, Sebastian Schaub, DVM, Dr. med. vet. DipECVDI  
sebast.schaub@gmail.com

**AGE**

3 Years

**INTERPRETED BY**

Sebastian Schaub, DVM  
Dr. med. vet. DipECVDI

**HOSPITAL NAME**

Bluegrass Veterinary  
Specialists

**REFERRING VET**

Guevara

**INVOICE**

49295

**DATE**

1-4-22