



PATIENT

Visa Roan

PRESENTING CLINICAL SIGNS

Abdominal Pathology
Abnormal PE/Chem/CBC/UA Results: CHEM 17/CBC/LYTES all within normal limits

SPECIES

Canine

COMPUTED TOMOGRAPHY OF THE ABDOMEN

A pre- and post-contrast CT study of the abdomen in a bone and soft tissue reconstruction is provided for review.

BREED

German Shepherd
Dog

COMPUTED TOMOGRAPHIC FINDINGS

The serosal fat presents normal attenuation behavior. There is no evidence of peritoneal effusion or peritonitis.

Both kidneys present within normal limits for size, shape and organ architecture. After contrast administration a bilaterally symmetric and uniform nephro- and pyelogram is noted.

SEX

Spayed Female

The adrenal glands are within normal limits for size, shape and organ architecture.

Both liver and spleen present with normal shape, even surface, uniformly attenuating parenchyma and homogeneous contrast enhancement, unremarkable.

AGE

9 Years, 2 Months

The portal vein presents a normal order of its tributary veins and intrahepatic branching. No abnormal vessel is noted inside and outside of the liver parenchyma.

The pancreas is evenly contoured, the pancreatic parenchyma is homogeneous and presents uniform contrast enhancement.

INTERPRETED BY

Sebastian Schaub, DVM
Dr. med. vet. DipECVDI

The cardia of the stomach is mildly displaced cranially to the diaphragm into the caudal mediastinum. The position, delineation, wall and content of the gastrointestinal tract are considered within normal limits throughout.

HOSPITAL NAME

Bluegrass Veterinary
Specialists

In the subcutaneous tissue along the left ventrolateral abdominal wall, a well-defined, uniform fat attenuating mass is seen, measuring 7.0 x 2.8 x 10.7 cm in size.

The medial iliac lymph nodes present mild mineralization of the parenchyma. The medial iliac lymph nodes are normal in size and shaped, the normal short-to-long-axis ratio is maintained.

REFERRING VET

Roan

Multifocal spondylosis formation is seen along the lumbar spine. The lumbosacral intervertebral disc is protruding into the vertebral canal, occupying approximately 50% of the cross-sectional area of the vertebral canal at the same level. Both coxofemoral joints present moderate osteophyte new bone formation.

COMPUTED TOMOGRAPHIC DIAGNOSIS

INVOICE

56496

- Mild dystrophic mineralization medial iliac lymph nodes
- Sliding hiatal hernia - likely a sequela to general anesthesia and decreased muscle tone of the diaphragm
- Degenerative lumbosacral stenosis with likely dynamic compression of the cauda equina fibers
- Lipoma left cranioventral abdominal wall
- Degenerative osteoarthritis coxofemoral joints bilaterally, due to hip dysplasia
- Spondylosis deformans

DATE

1-31-23



PATIENT

Visa Roan

SPECIES

Canine

BREED

German Shepherd
Dog

SEX

Spayed Female

AGE

9 Years, 2 Months

INTERPRETED BY

Sebastian Schaub, DVM
Dr. med. vet. DipECVDI

HOSPITAL NAME

Bluegrass Veterinary
Specialists

REFERRING VET

Roan

INVOICE

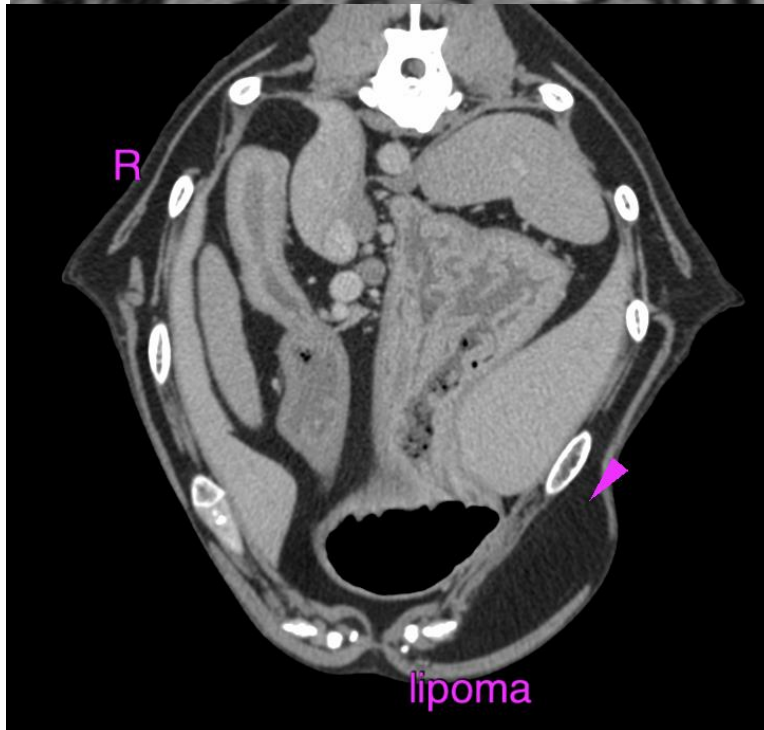
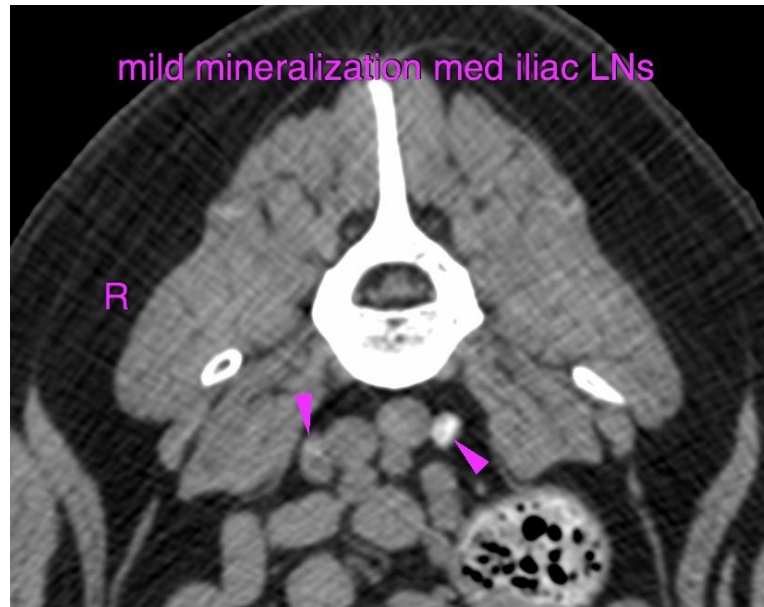
56496

DATE

1-31-23

INTERPRETATION OF THE FINDINGS & FURTHER RECOMMENDATIONS

The CT study presents without clinically relevant pathologies of the abdominal organs. The mild dystrophic mineralization of the medial iliac lymph nodes can be a sequela to preceding inflammation – consider FNA sampling if there is suspicion for malignant infiltration.





PATIENT

Visa Roan

The information and recommendations provided are based on the images presented by the referring veterinarian/sonographer. No evaluation can be communicated regarding pathology that was not visible in the image/video clips provided.

SPECIES

Canine

Thank you for this referral. If the clinical or image interpretation does not parallel your findings or if I can be of any further assistance please contact me.

BREED

German Shepherd
Dog

Sebastian Schaub, Sebastian Schaub, DVM, Dr. med. vet. DipECVDI
sebast.schaub@gmail.com

SEX

Spayed Female

AGE

9 Years, 2 Months

INTERPRETED BY

Sebastian Schaub, DVM
Dr. med. vet. DipECVDI

HOSPITAL NAME

Bluegrass Veterinary
Specialists

REFERRING VET

Roan

INVOICE

56496

DATE

1-31-23