



**PATIENT**

Mitzi Baker

**PRESENTING CLINICAL SIGNS**

Pet presented today for a dental cleaning with imaging

**SPECIES**

Canine

**COMPUTED TOMOGRAPHY OF THE SKULL**

A high resolution pre- and post-contrast CT study of the skull is provided for review.

**BREED**

Pomeranian

**COMPUTED TOMOGRAPHIC FINDINGS**

Triadan 311 and 411 are absent. The crown of triadan 306 is separated from the roots. A generalized mild horizontal bone loss is seen level with the upper and lower incisor teeth. The remainder of the dentition present without abnormalities.

**SEX**

FS

**COMPUTED TOMOGRAPHIC DIAGNOSIS**

- Complicated dental fracture 306
- Generalized periodontal disease upper and lower incisor teeth with horizontal bone loss.

**AGE**

2 Years

**INTERPRETATION OF THE FINDINGS & FURTHER RECOMMENDATIONS**

There is evidence of dental fracture of triadan 306 – extraction of the respective dental element is the therapy of choice. A complete dental workup has already been performed, regarding the history.

**INTERPRETED BY**

Sebastian Schaub, DVM  
Dr. med. vet. DipECVDI

**HOSPITAL NAME**

Cranberry Holistic  
Pet Care

**REFERRING VET**

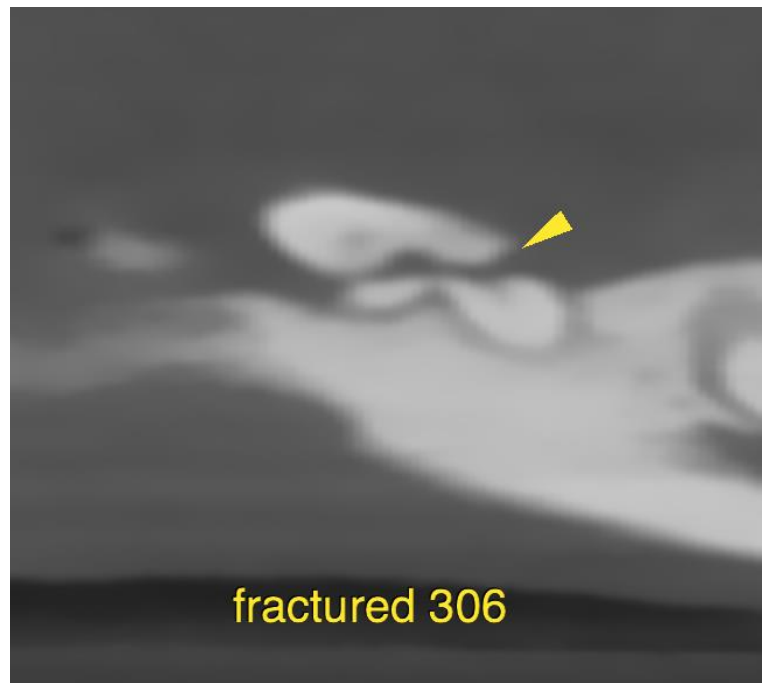
Cynthia Maro

**INVOICE**

56471

**DATE**

1-31-23





**PATIENT**

Mitzi Baker

**SPECIES**

Canine

**BREED**

Pomeranian

**SEX**

FS

**AGE**

2 Years

**INTERPRETED BY**

Sebastian Schaub, DVM  
Dr. med. vet. DipECVDI

**HOSPITAL NAME**

Cranberry Holistic  
Pet Care

**REFERRING VET**

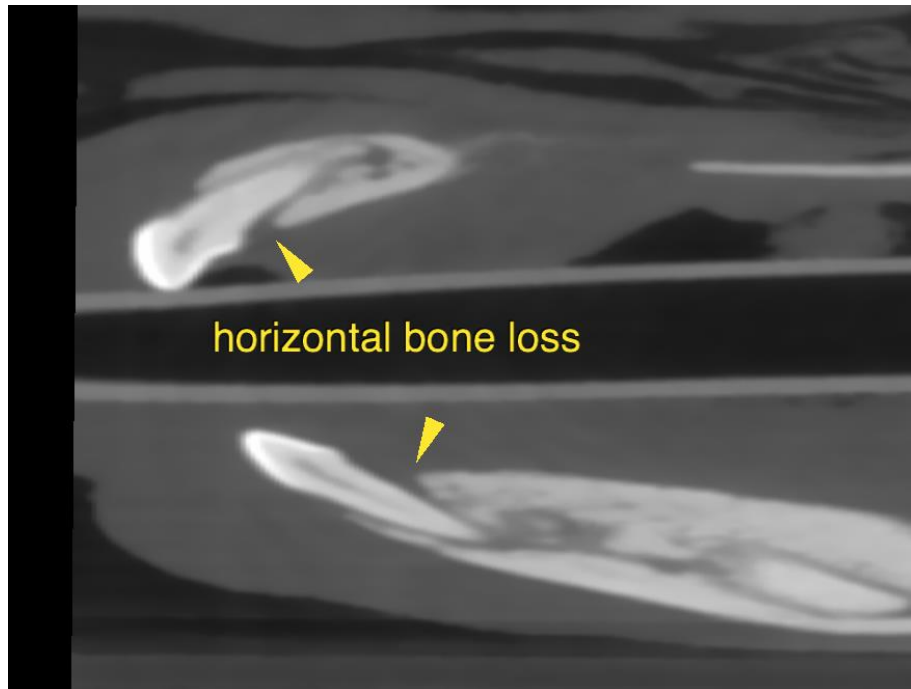
Cynthia Maro

**INVOICE**

56471

**DATE**

1-31-23



The information and recommendations provided are based on the images presented by the referring veterinarian/sonographer. No evaluation can be communicated regarding pathology that was not visible in the image/video clips provided.

Thank you for this referral. If the clinical or image interpretation does not parallel your findings or if I can be of any further assistance please contact me.

**Sebastian Schaub**, Sebastian Schaub, DVM, Dr. med. vet. DipECVDI  
sebast.schaub@gmail.com