



PATIENT PRESENTING CLINICAL SIGNS

Margo Burley History of elevated ALT and ALP, Albumin is on the lower end of normal. Pet also has proteinuria and is currently on Benazepril. On PE, abdomen was tense on palpation, sq cyst on L hip. Bile acids recommended but has not been done yet. Unsure if clinical signs of PU/PD, but urine appears diluted.

SPECIES Abnormal PE/Chem/CBC/UA Results: PLT: 787 ALT: 176 ALP: 631 Alb: 2.7 UA SG: 1.005 UPC: 2.0, no active sediment

Canine COMPUTED TOMOGRAPHY OF THE ABDOMEN

A high resolution pre- and post-contrast CT study of the abdomen is provided for review.

BREED COMPUTED TOMOGRAPHIC FINDINGS

Terrier Mix The serosal fat presents normal attenuation behavior. There is no evidence of peritoneal effusion or peritonitis.

SEX Both kidneys present within normal limits for size, shape and organ architecture. After contrast administration a both kidneys present with small (<2 mm) parenchymal filling defects.

SF The adrenal glands are within normal limits for size, shape and organ architecture.

AGE The spleen presents with normal shape, even surface. The parenchyma of the body of the spleen presents a roundish hypoattenuating region in the pre and post contrast series.

11 Years The hepatic volume is moderately increased, the liver is protruding caudally beyond the costal arch and the caudoventral hepatic margins are rounded. The gastric axis is deviated caudally. Throughout the hepatic parenchyma, multiple well-defined parenchymal filling defects are appreciated, measuring up to 2.1 cm in size.

INTERPRETED BY

Sebastian Schaub, DVM
Dr. med. vet. DipECVDI

The portal vein presents a normal order of its tributary veins and intrahepatic branching. No abnormal vessel is noted inside and outside of the liver parenchyma.

HOSPITAL NAME

Mobile Pet Imaging
CFL

The pancreas is evenly contoured, the pancreatic parenchyma is homogeneous and presents uniform contrast enhancement.

The position, delineation, wall and content of the gastrointestinal tract are considered within normal limits throughout.

REFERRING VET

Xavier Meaux

In the subcutaneous tissue of the left flank, a well-defined, soft tissue attenuating nodule, measuring 7 mm in diameter is appreciated.

The intervertebral disc space L2/L3 is moderately narrowed and increased sclerosis of the subchondral bone of the respective vertebral endplates is appreciated. Level with the intervertebral disc space L4/L5, mineralized disc material is mildly bulging into the vertebral canal, distorting the ventral epidural space.

INVOICE

56469

COMPUTED TOMOGRAPHIC DIAGNOSIS

- Hepatomegaly
- Hepatic cysts
- Mild heterogeneous attenuation pattern spleen
- Intervertebral disc protrusion L4/L5 with possible dynamic myelocompression
- Chronic discopathy L2/L3

DATE

1-31-23



- PATIENT**
- Renal cysts
 - Non-specific subcutaneous nodule left flank.

Margo Burley

INTERPRETATION OF THE FINDINGS & FURTHER RECOMMENDATIONS

SPECIES Potentials for the hepatomegaly include metabolic hepatic disease, hepatitis or diffuse neoplastic infiltration. In case of doubt, ultrasound guided FNA sampling and/or Tru-cut biopsy can be used as minimally invasive methods for further workup.

Canine

The hepatic cysts are considered incidental.

BREED The mild heterogeneous attenuation pattern of the spleen can be caused by nodular lymphoid hyperplasia or myelolipoma. The odds for neoplastic infiltration of the spleen are considered low. In case of doubt, ultrasound guided FNA sampling is recommended.

Terrier Mix

SEX

SF

AGE

11 Years

INTERPRETED BY

Sebastian Schaub, DVM
Dr. med. vet. DipECVDI

HOSPITAL NAME

Mobile Pet Imaging
CFL

REFERRING VET

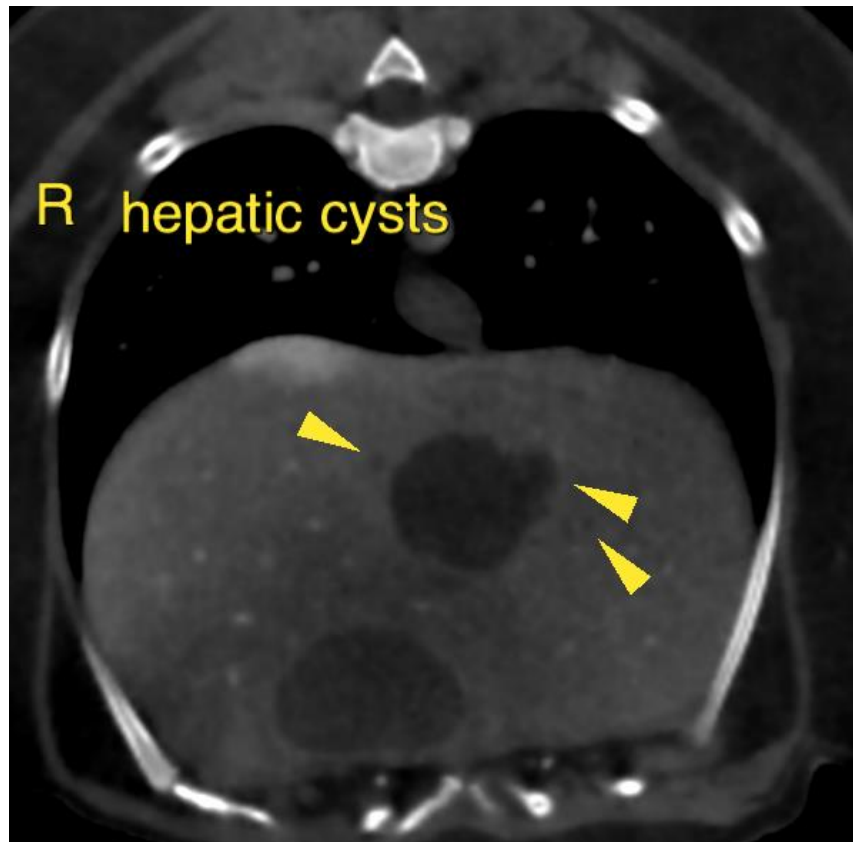
Xavier Meaux

INVOICE

56469

DATE

1-31-23





PATIENT

Margo Burley

SPECIES

Canine

BREED

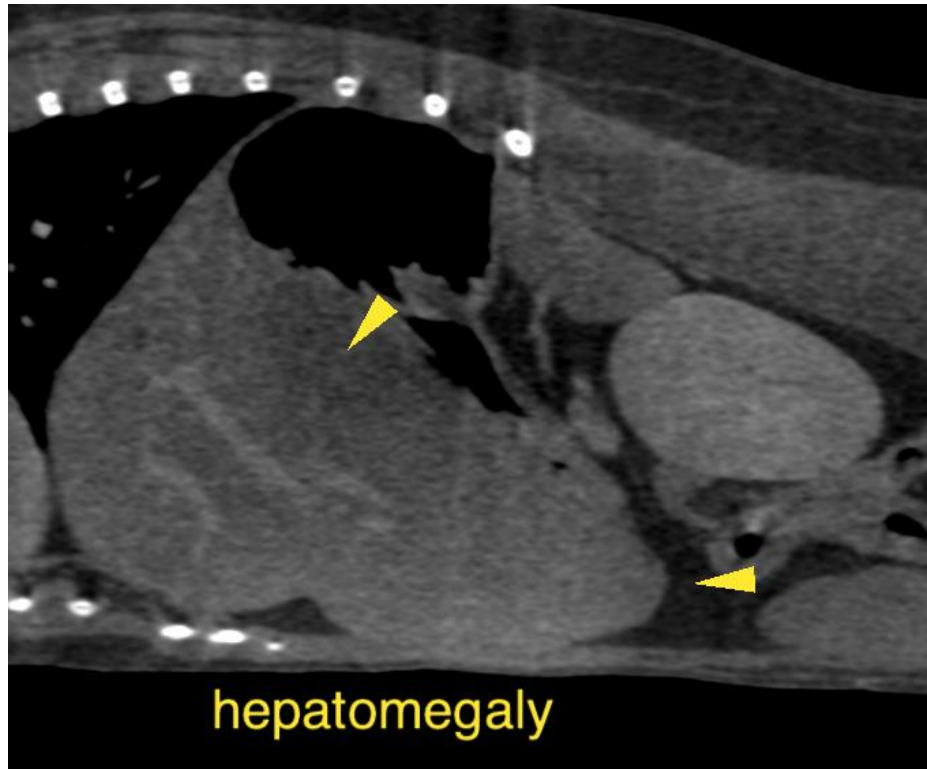
Terrier Mix

SEX

SF

AGE

11 Years



INTERPRETED BY

Sebastian Schaub, DVM
Dr. med. vet. DipECVDI

HOSPITAL NAME

Mobile Pet Imaging
CFL

REFERRING VET

Xavier Meaux

The information and recommendations provided are based on the images presented by the referring veterinarian/sonographer. No evaluation can be communicated regarding pathology that was not visible in the image/video clips provided.

Thank you for this referral. If the clinical or image interpretation does not parallel your findings or if I can be of any further assistance please contact me.

Sebastian Schaub, Sebastian Schaub, DVM, Dr. med. vet. DipECVDI
sebast.schaub@gmail.com

INVOICE

56469

DATE

1-31-23