



PATIENT

Pearl Crookes

PRESENTING CLINICAL SIGNS

Recurrent anemia and increased respiratory rate/effort, scant free abdominal fluid and possible pleural effusion present. Ddx: neoplasia vs IMHA vs slow bleed
Abnormal PE/Chem/CBC/UA Results: PCV 23% non regenerative, neutrophilia

SPECIES

Canine

COMPUTED TOMOGRAPHY OF THE THORAX AND ABDOMEN

A high resolution pre- and post-contrast CT study of the thorax and abdomen are provided for review.

BREED

Jack Russell Terrier

COMPUTED TOMOGRAPHIC FINDINGS

The body condition score is 9/9.

SEX

FS

Thorax

The 10th to 13th right rib present a segmental smooth widening in the proximal segment.

AGE

10 Years, 2 Months

The sternal, cranial mediastinal and tracheobronchial lymph nodes are small elongated with a normal short-to-long-axis-ratio is < 0.5, the attenuation and contrast enhancement pattern is uniform and considered within normal limits.

The mediastinum is moderately widened by fat.

INTERPRETED BY

Sebastian Schaub, DVM
Dr. med. vet. DipECVDI

The cardiovascular structures including the pulmonary vasculature are within normal limits.

The bronchial tree presents with regular branching and tapers uniformly towards the periphery as expected, the bronchial walls are thin and smooth. The bronchus-to-artery ratio is within normal limits.

HOSPITAL NAME

Bridgwater
Veterinary Hospital
and Wellness Centre

The lung parenchyma presents the expected architecture and attenuation behavior, but regions of compression atelectasis of the caudodorsal dependent aspects of the lung.

Small incidental gas pockets are seen within the esophageal lumen, there is no evidence of abnormal dilation.

REFERRING VET

Dr. J. Shapera

Abdomen

The serosal fat presents normal attenuation behavior. There is no evidence of peritoneal effusion or peritonitis.

INVOICE

49969

Both kidneys present within normal limits for size, shape and organ architecture. After contrast administration a bilaterally symmetric and uniform nephro- and pyelogram is noted.

The adrenal glands are within normal limits for size, shape and organ architecture.

DATE

1-31-22

Both liver and spleen present with normal shape, even surface, uniformly attenuating parenchyma and homogeneous contrast enhancement, unremarkable.

A small amount of mineralized biliary sludge is visible in the gallbladder.



PATIENT

Pearl Crookes

The pancreas is evenly contoured, the pancreatic parenchyma is homogeneous and presents uniform contrast enhancement.

SPECIES

Canine

The position, delineation, wall and content of the gastrointestinal tract are considered within normal limits throughout.

Multifocal mild spondylosis formation is seen along the lumbar spine.

BREED

Jack Russell Terrier

COMPUTED TOMOGRAPHIC DIAGNOSIS

- Obesity
- Compression atelectasis caudodorsal dependent aspects of the lung
- Healed proximal costal fracture 10th to 13th rib
- Spondylosis deformans
- Normal abdomen

SEX

FS

INTERPRETATION OF THE FINDINGS & FURTHER RECOMMENDATIONS

The CT study presents without clinically relevant pathology, but the obesity of the patient. The negative CT study might support the diagnosis of immune hemolytic anemia or myeloproliferative pathology – based on results of the lab work, bone marrow biopsy might be used as advanced diagnostic test.

AGE

10 Years, 2 Months

INTERPRETED BY

Sebastian Schaub, DVM
Dr. med. vet. DipECVDI

HOSPITAL NAME

Bridgwater
Veterinary Hospital
and Wellness Centre

REFERRING VET

Dr. J. Shapera

INVOICE

49969

DATE

1-31-22



PATIENT

Pearl Crookes

SPECIES

Canine

BREED

Jack Russell Terrier

SEX

FS

AGE

10 Years, 2 Months

INTERPRETED BY

Sebastian Schaub, DVM
Dr. med. vet. DipECVDI

HOSPITAL NAME

Bridgwater
Veterinary Hospital
and Wellness Centre

REFERRING VET

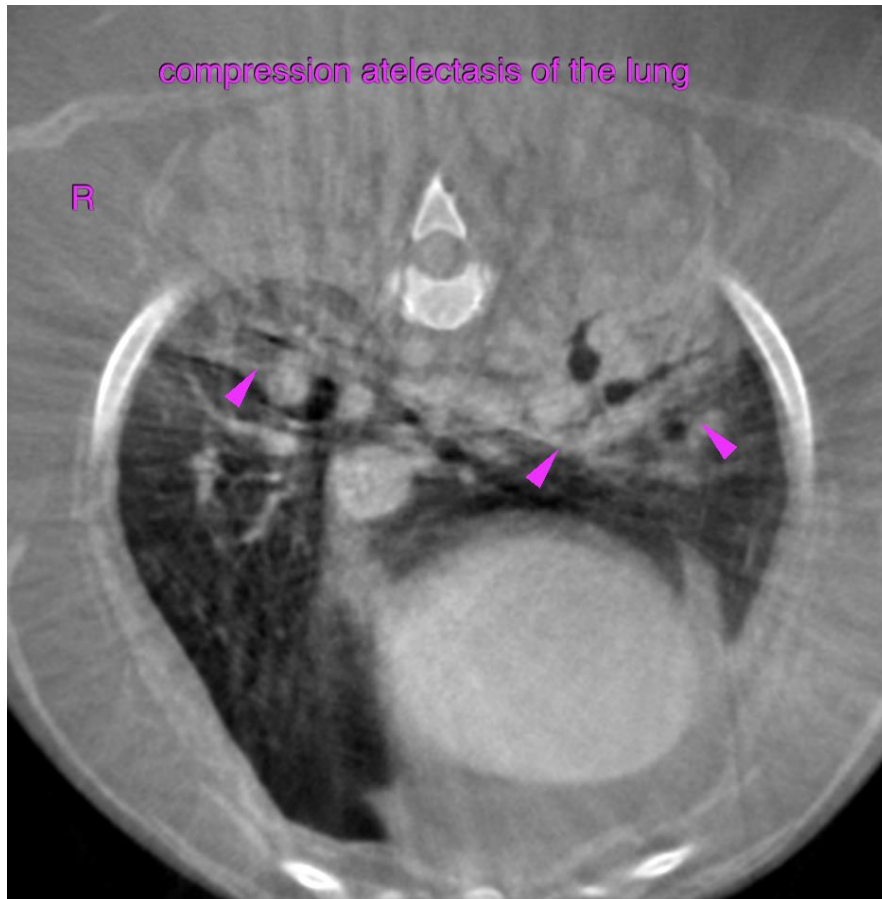
Dr. J. Shapera

INVOICE

49969

DATE

1-31-22



The information and recommendations provided are based on the images presented by the referring veterinarian/sonographer. No evaluation can be communicated regarding pathology that was not visible in the image/video clips provided.

Thank you for this referral. If the clinical or image interpretation does not parallel your findings or if I can be of any further assistance please contact me.

Sebastian Schaub, Sebastian Schaub, DVM, Dr. med. vet. DipECVDI
sebast.schaub@gmail.com