



PATIENT

Lucky Leland

SPECIES

Canine

BREED

German Shorhaired
Pointer

SEX

Male

AGE

2 Years, 7 Months

INTERPRETED BY

Sebastian Schaub, DVM
Dr. med. vet. DipECVDI

HOSPITAL NAME

Elizabeth Animal
Hospital

REFERRING VET

Leon Anderson, DVM

INVOICE

49971

DATE

1-31-22

PRESENTING CLINICAL SIGNS

Ran into a pole 11 days ago. Fully recovered and was normal until 2 days ago and developed swelling around his left shoulder/chest area. Swelling goes down overnight with rest then comes back with activity.

Abnormal PE/Chem/CBC/UA Results: Not lame at all. Acts fine. Swelling left pectoral axillary brachial area.

RADIOGRAPHIC STUDY OF THE SHOULDER JOINTS

Radiographs of the shoulder joints in two orthogonal imaging planes are provided for review.

RADIOGRAPHIC FINDINGS

The left shoulder joint is superimposed on the sternum. The periarticular bones of the left shoulder joint present mild osteophyte new bone formation. A significant soft tissue swelling is seen at the cranial aspect of the left shoulder joint/left brachium.

The periarticular bones of the right shoulder joint have smooth osseous margins.

No abnormalities of the surrounding soft tissue structures of the shoulder joints are appreciated.

RADIOGRAPHIC DIAGNOSIS

- Soft tissue swelling left prescapular region/cranial aspect left brachium
- Mild degenerative osteoarthritis left shoulder joint

INTERPRETATION OF THE FINDINGS & FURTHER RECOMMENDATIONS

An underlying cause for the soft tissue swelling at the cranial aspect of the left brachium is not appreciated and potentials include seroma, hematoma, edema (e.g. mast cell tumor), inflammatory origin, traumatic arterio-venous fistula formation, other. An ultrasound examination of the respective region can be considered as advanced imaging modality and to screen for evidence of free fluid or signs of vascular abnormalities.



PATIENT

Lucky Leland

SPECIES

Canine

BREED

German Shorhaired
Pointer

SEX

Male

AGE

2 Years, 7 Months

INTERPRETED BY

Sebastian Schaub, DVM
Dr. med. vet. DipECVDI

HOSPITAL NAME

Elizabeth Animal
Hospital

REFERRING VET

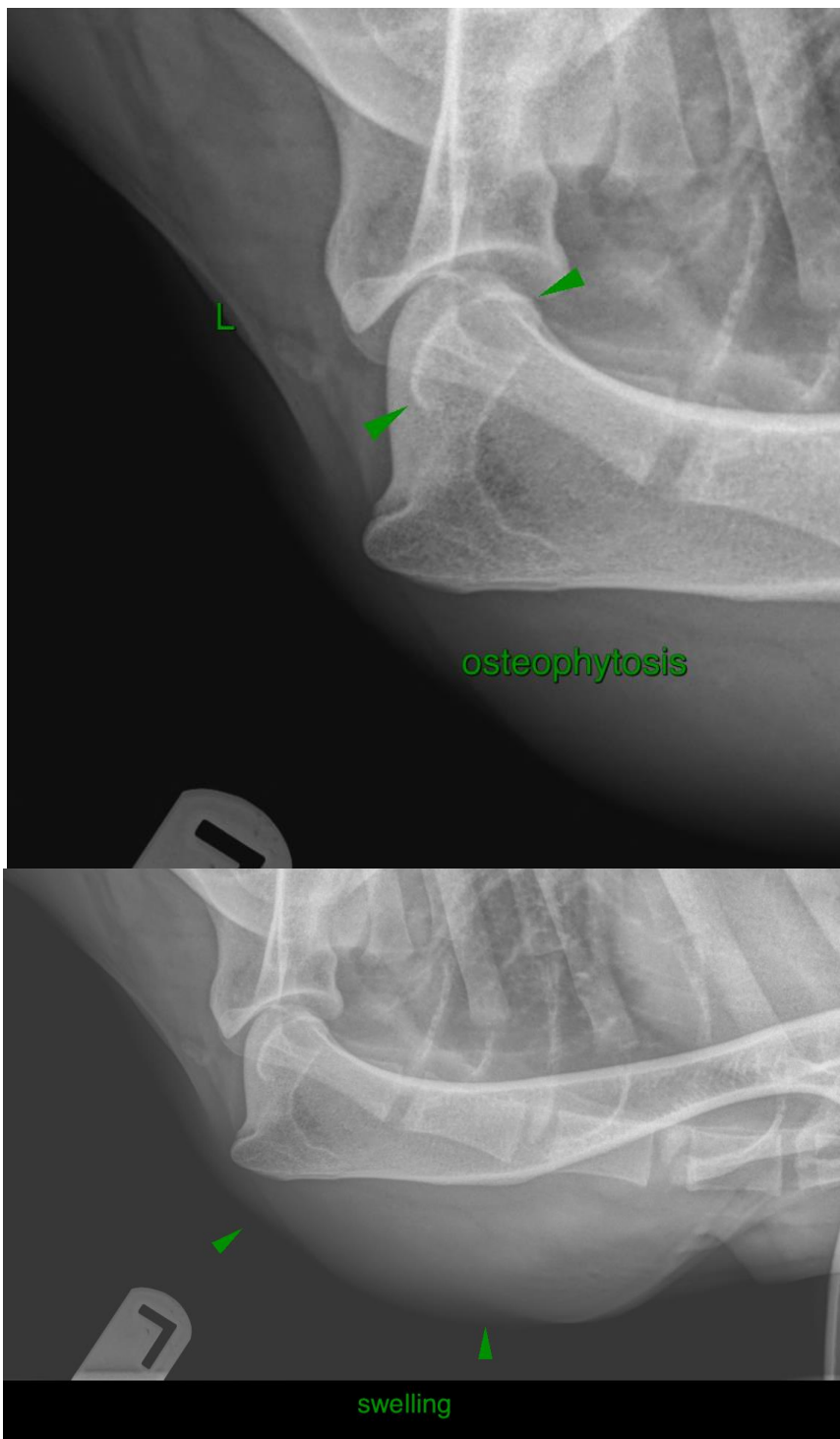
Leon Anderson, DVM

INVOICE

49971

DATE

1-31-22





PATIENT

Lucky Leland

SPECIES

Canine

The information and recommendations provided are based on the images presented by the referring veterinarian/sonographer. No evaluation can be communicated regarding pathology that was not visible in the image/video clips provided.

BREED

German Shorhaired
Pointer

Thank you for this referral. If the clinical or image interpretation does not parallel your findings or if I can be of any further assistance please contact me.

Sebastian Schaub, Sebastian Schaub, DVM, Dr. med. vet. DipECVDI
sebast.schaub@gmail.com

SEX

Male

AGE

2 Years, 7 Months

INTERPRETED BY

Sebastian Schaub, DVM
Dr. med. vet. DipECVDI

HOSPITAL NAME

Elizabeth Animal
Hospital

REFERRING VET

Leon Anderson, DVM

INVOICE

49971

DATE

1-31-22