



PATIENT

Kobe Sheik

PRESENTING CLINICAL SIGNS

Kobe came in 4 weeks ago as she had head tilt to the left side for the last 2 weeks and concern of weak legs. 2 weeks ago came back with some improvement but his left hind leg was weak and he was keep falling when he put weight on his left hind leg, sent home with meloxicam and AB. today Kobe came with no improvement on his medication and still limping on left hind leg

SPECIES

Feline

RADIOGRAPHIC STUDY OF THE PELVIS & STIFLE JOINTS

Radiographs of the pelvis and stifle joints in two imaging planes are provided for review.

BREED

Selkirk Rex

RADIOGRAPHIC FINDINGS

An innumerable amount of roundish small (< 0.5 mm) mineralized bodies are seen in the imaging plane of the urinary bladder.

SEX

MN

The left iliac wing presents mild irregular lateral margin in the VD projection - no abnormalities are appreciated in the oblique faux profile of the left iliac wing.

AGE

16 Years

The acetabular groove of both coxofemoral joints is shallow. The center of both femoral heads is lateral to the dorsal acetabular rim.

Small irregular mineralized bodies are superimposed on the cranial compartment of the left & right stifle joint.

INTERPRETED BY

Sebastian Schaub, DVM
Dr. med. vet. DipECVDI

RADIOGRAPHIC DIAGNOSIS

- Bilateral hip dysplasia
- Suspect meniscal mineralization left & right stifle joint
- Cystolithiasis

HOSPITAL NAME

Brittany Glen Animal
Hospital

INTERPRETATION OF THE FINDINGS & FURTHER RECOMMENDATIONS

No specific abnormality is appreciated, explaining the weakness of the left hind limb. The meniscal mineralization and the hip dysplasia are likely an incidental finding. However, test for potential instability of the left stifle joint.

REFERRING VET

Dr. Boktor

The mild irregularity of the left iliac wing is considered as normal conformation of the dorsal margin, as no abnormality can be appreciated in the oblique projection of the pelvis.

Rule out thromboembolic disease or underlying pathology of the CNS.

INVOICE

49972

DATE

1-31-22



PATIENT

Kobe Sheik

SPECIES

Feline

BREED

Selkirk Rex

SEX

MN

AGE

16 Years

INTERPRETED BY

Sebastian Schaub, DVM
Dr. med. vet. DipECVDI

HOSPITAL NAME

Brittany Glen Animal
Hospital

REFERRING VET

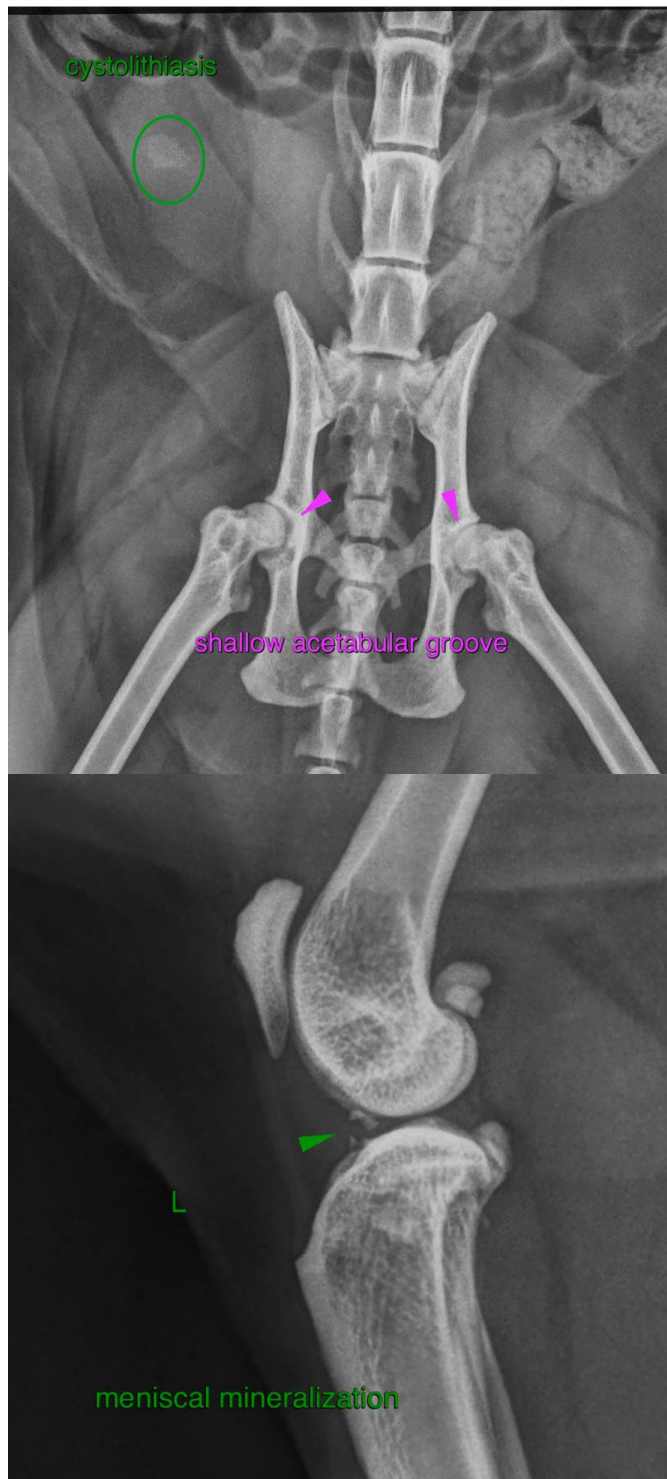
Dr. Boktor

INVOICE

49972

DATE

1-31-22





PATIENT

Kobe Sheik

SPECIES

Feline

BREED

Selkirk Rex

SEX

MN

AGE

16 Years

INTERPRETED BY

Sebastian Schaub, DVM
Dr. med. vet. DipECVDI

HOSPITAL NAME

Brittany Glen Animal
Hospital

REFERRING VET

Dr. Boktor

INVOICE

49972

DATE

1-31-22

The information and recommendations provided are based on the images presented by the referring veterinarian/sonographer. No evaluation can be communicated regarding pathology that was not visible in the image/video clips provided.

Thank you for this referral. If the clinical or image interpretation does not parallel your findings or if I can be of any further assistance please contact me.

Sebastian Schaub, Sebastian Schaub, DVM, Dr. med. vet. DipECVDI
sebast.schaub@gmail.com