



PATIENT

Venus Goldberg

SPECIES

Canine

BREED

American Pit

SEX

FS

AGE

10Y

WEIGHT

19.7kg

INTERPRETED BY

Sebastian Schaub, DVM
Dr. med. vet.
DipECVDI

IMAGING PERFORMED BY

AS/AM

HOSPITAL NAME

Green Dog Dental and
Wellness

REFERRING VET

Dr Geist

INVOICE

73536

DATE

1-29-26

PRESENTING CLINICAL SIGNS

CT/rhinology procedure for bilateral nasal discharge and stertor. Owner reports she is still coughing/hacking occasionally. It has not subsided completely but still improved markedly since onset of aspiration pneumonia ~1 month ago.

COMPUTED TOMOGRAPHY OF THE SKULL

A high resolution pre- and post-contrast CT study of the skull is provided for review.

COMPUTED TOMOGRAPHIC FINDINGS

The caudal aspect of the neurocranium is cropped by the field of view.

The tooth elements 301-303, 401-403, 410 and 411 are absent.

In both nasal cavities a moderate amount of fluid attenuating material is attached to the thickened nasal mucosal lining.

Both temporomandibular joints present congruent joint spaces with even subchondral bone surfaces and are considered within normal limits.

Both tympanic bullae are aerated, the mucosal lining is not seen, the bony wall is smooth and thin. The external ear canals are within normal limits.

The brain presents no deviation from normal anatomy and symmetry. The brain parenchyma is homogeneous and within normal limits for attenuation and distribution of contrast enhancement. The ventricular system is non-dilated and symmetric.

COMPUTED TOMOGRAPHIC DIAGNOSIS

- Rhinitis
- Multiple absent teeth, see above

INTERPRETATION OF THE FINDINGS & FURTHER RECOMMENDATIONS

The CT study is consistent with rhinitis, and the presumptive diagnosis is non-specific rhinitis (e.g. allergic, lymphocytic plasmocytic, eosinophilic). There is no evidence of nasal mass, foreign body, mycotic rhinitis or odontogenic rhinitis. Rhinoscopy including biopsy can be used for further workup. Accompanying bronchitis/bronchopneumonia can occur.



PATIENT

Venus Goldberg

SPECIES

Canine

BREED

American Pit

SEX

FS

AGE

10Y

WEIGHT

19.7kg

INTERPRETED BY

Sebastian Schaub, DVM
Dr. med. vet.
DipECVDI

IMAGING PERFORMED BY

AS/AM

HOSPITAL NAME

Green Dog Dental and
Wellness

REFERRING VET

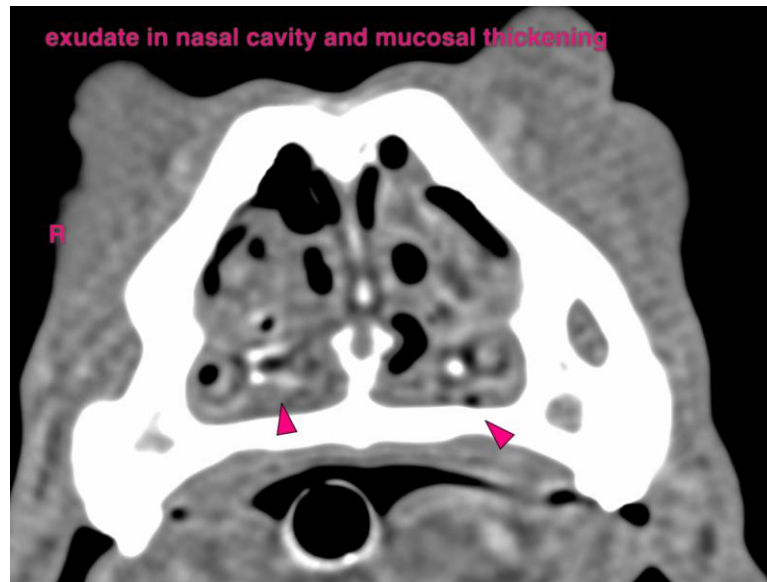
Dr Geist

INVOICE

73536

DATE

1-29-26



The information and recommendations provided are based on the images presented by the referring veterinarian/sonographer. No evaluation can be communicated regarding pathology that was not visible in the image/video clips provided.

Thank you for this referral. If the clinical or image interpretation does not parallel your findings or if I can be of any further assistance please contact me.

Sebastian Schaub, Sebastian Schaub, DVM, Dr. med. vet. DipECVDI
info@sonopath.com