



PATIENT PRESENTING CLINICAL SIGNS

PATIENT Kate Piculell
SPECIES Canine
BREED Labrador Retriever
SEX FS
AGE 14
INTERPRETED BY Sebastian Schaub, DVM
 Dr. med. vet. DipECVDI

Being hosp for pneumonia. Went in to regular veterinarian on 1/25 for anorexia and lethargy. They started on antibiotics and NSAID for possible mouth infection (hx of tooth root abscess) and hip pain, received baytril and metacam. Had not been improving and represented to pDVM 1/27. Xrays showed right sided pneumonia (initial concern for mass) and neutropenia. T was 104.2 at pDVM. Presented to Wilvet Salem on 1/27 in the evening. Submitted Xrays showed concern for pneumonia, no obvious mass. CBC with path review showed adequate neut with bands. Placed on Oxygen, urinary catheter/recumbancy care, antibiotics and GI supportive care. P has been obtunded and not willing to get up, did eat a small amount 1/28 during the day. SPO2 has remained wnl. Still mildly dyspneic but not worse. 1. Severe consolidation and air bronchogram of the R middle and caudal lung lobes - There is concern for neoplasia based on: Heptatized lung on VetBLUE, Appearance of the lung on radiographs, look more like a mass affect than an air bronchogram, chronicity of weight loss with severe cachexia, anemia of chronic disease, and that the patient is not as "clinical" as her radiographs - that she is compensating relatively well makes me concerned that it is likely a chronic process such as neoplasia. 2. Mild Anemia - non-regenerative (likely anemia of chronic disease). 3. Anorexia, lethargy 4. Elevated ALP 5. Elevated BUN
 Abnormal PE/Chem/CBC/UA Results: 1/27 CBC: Hct 35.6%, WBC 11.51 Neut 0.16 Lymp 7.05 Mono 4.29 Chem: ALP 227 (rr 23-212), BUN 32 Creat 1.7 (rr 0.5-1.8) PT/PTT- within reference range 12/77 1/28 8am EPOC Hct 38, BUN 31 Na 156 Cl 133 PCV/TS: 40/8.2
 Urinalysis: USG 1.025 (was already on fluids), pH 6.0, protein 100mg/dL, blood 250 ery/uL, WBC's 12 phpf, RBC's 6 phpf, cocci and bacteria suspect presence, squamous epithelial cells < 1/phpf, non-squamous epithelial cells 3-5phpf, non-hyalanine casts > 1 per low power field, < 1 unclassified crystals.

COMPUTED TOMOGRAPHY OF THE THORAX

A high resolution plain CT study of the thorax is provided for review.

HOSPITAL NAME COMPUTED TOMOGRAPHIC FINDINGS

HOSPITAL NAME Wilvet Salem
REFERRING VET Dr. Amber Schofield, DVM

The intervertebral disc spaces C5/C6, C6/C7, T3/T4 to T9/T10 and L1/L2 are collapsed. The subchondral bone of the caudal vertebral endplates of C6/C7, multifocal along the mid thoracic spine and L1/L2 presents with multiple geographic osteolytic lesions and moderate sclerosis. The periarticular bones of the left shoulder joint present moderate osteophyte new bone formation.

The sternal, cranial mediastinal and tracheobronchial lymph nodes are small elongated with a normal short-to-long-axis-ratio is < 0.5, the attenuation pattern is uniform and considered within normal limits.

INVOICE The cardiovascular structures including the pulmonary vasculature are within normal limits.

49929 The ventral dependent aspects of the right lung lobes are soft tissue attenuating with air-bronchograms, the volume of the respective lung lobes is maintained. The remainder of the hepatic parenchyma are aerated and present the expected architecture.

DATE 1-29-22 Small incidental gas pockets are seen within the esophageal lumen, there is no evidence of abnormal dilation.



PATIENT

Kate Piculell

COMPUTED TOMOGRAPHIC DIAGNOSIS

- Ventrally distributed alveolar pattern right lung lobes
- Advanced degenerative disc disease multifocal along the cervical & thoracic spine with osseous remodeling of the vertebral endplates
- Degenerative osteoarthritis left shoulder joint
- Spondylosis deformans

SPECIES

Canine

INTERPRETATION OF THE FINDINGS & FURTHER RECOMMENDATIONS

BREED

Labrador Retriever

Regarding the distribution of the alveolar pattern, the top differential is bacterial pneumonia or pulmonary hemorrhage. Also considered less likely here, diffuse neoplastic infiltration might be a consideration if the pulmonary pattern is stationary under therapy – FNA sampling can be used as advanced diagnostic test.

SEX

FS

AGE

14

INTERPRETED BY

Sebastian Schaub, DVM
Dr. med. vet. DipECVDI

HOSPITAL NAME

Wilvet Salem

REFERRING VET

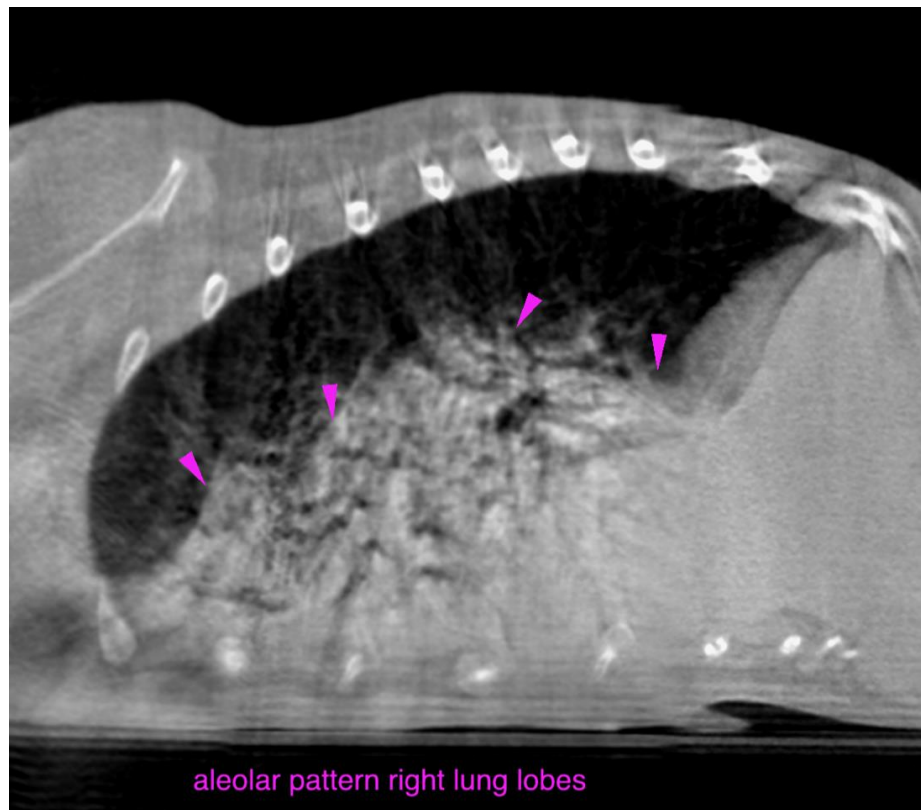
Dr. Amber Schofield,
DVM

INVOICE

49929

DATE

1-29-22





PATIENT

Kate Piculell

The information and recommendations provided are based on the images presented by the referring veterinarian/sonographer. No evaluation can be communicated regarding pathology that was not visible in the image/video clips provided.

Thank you for this referral. If the clinical or image interpretation does not parallel your findings or if I can be of any further assistance please contact me.

SPECIES

Canine

Sebastian Schaub, Sebastian Schaub, DVM, Dr. med. vet. DipECVDI
sebast.schaub@gmail.com

BREED

Labrador Retriever

SEX

FS

AGE

14

INTERPRETED BY

Sebastian Schaub, DVM
Dr. med. vet. DipECVDI

HOSPITAL NAME

Wilvet Salem

REFERRING VET

Dr. Amber Schofield,
DVM

INVOICE

49929

DATE

1-29-22