



PATIENT

Scottie Cat Posse

SPECIES

Feline

BREED

DSH

SEX

Male Neutered

AGE

17Y, 27D

WEIGHT

7.8

INTERPRETED BY

Sebastian Schaub, DVM
Dr. med. vet.
DipECVDI

IMAGING PERFORMED BY

DTLAvets

HOSPITAL NAME

DTLAvets

REFERRING VET

Dr. Castaneda

INVOICE

73522

DATE

1-28-26

PRESENTING CLINICAL SIGNS

Jun 2025 rads revealed localized alveolar infiltrate, L cd lobe (per DACVR); then recheck rads in Aug 2025 revealed zone of pulmonary consolidation ventral aspect L cd lung lobe - appears to be stationary in size - finding is non specific and potentials include pyogranulomatous pneumonia, granuloma or neoplastic pulmonary transformation; hx hyperthyroidism - on Methimazole; hx FIV; hx asthma - started Fluticasone in 2024 = ZERO cough

RADIOGRAPHIC STUDY OF THE THORAX AND ABDOMEN

A complete set of radiographs of the thorax and abdomen are provided for review.

RADIOGRAPHIC FINDINGS

Thorax

Along the thoracic spine, multifocal mild spondylosis formation is seen.

The extrathoracic soft tissues present homogeneous without abnormalities.

The heart is of normal size and shape; there is no evidence of cardiac chamber or vascular enlargement. The cardiac silhouette presents age related rotation with secondary broad sternal contact. The pulmonary vasculature is within normal limits.

The trachea is normal in diameter and presents the anticipated course. The luminal outline of the trachea is smooth.

The bronchial tree presents with thin walls and tapers uniformly towards the periphery as expected.

The lung parenchyma presents the expected architecture and opacity – but an ill-defined zone with ground glass opacity in the ventral aspect of the left caudal lung lobe; the intrapulmonary vascular branching is seen up to the third order lung vessels.

The diaphragm is well delineated with even surface and the expected mild cranial bulging of the diaphragmatic cupola.

Abdomen

The lumbar spine presents multifocal spondylosis formation. Multiple facet joints along the lumbar spine present advanced osteophyte new bone formation.

No abnormalities of the extraabdominal soft tissues are noted. The abdominal wall is smooth and thin.

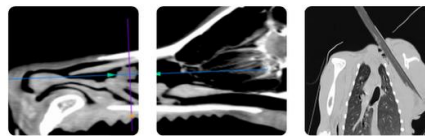
The serosal detail is maintained throughout the peritoneal and retroperitoneal space.

The liver is appropriate in position, size and presents uniform opacity.

The splenic head is in the anticipated position and within normal limits for size and opacity. The splenic body and tail are considered normal for position, size, shape and opacity.

Both kidneys are seen and present with normal size, shape, delineation and opacity. A small amount of mineral opaque material is seen in the image plane of the renal pelvis. The urinary bladder is empty and cannot be clearly delineated – suspect caudal position. No radiopaque calculi are noted throughout the upper and lower urinary tract.

The stomach is in its anticipated position and presents normal content.



PATIENT

Scoutie Cat Posse

SPECIES

Feline

BREED

DSH

SEX

Male Neutered

AGE

17Y, 27D

WEIGHT

7.8

INTERPRETED BY

Sebastian Schaub, DVM
Dr. med. vet.
DipECVDI

IMAGING PERFORMED BY

DTLAvets

HOSPITAL NAME

DTLAvets

REFERRING VET

Dr. Castaneda

INVOICE

73522

DATE

1-28-26

The small intestinal loops are of even diameter and non-dilated, a small amount of gas is seen within the small intestinal loops and considered within normal limits.

The colon is seen in the expected position and presents with appropriate content.

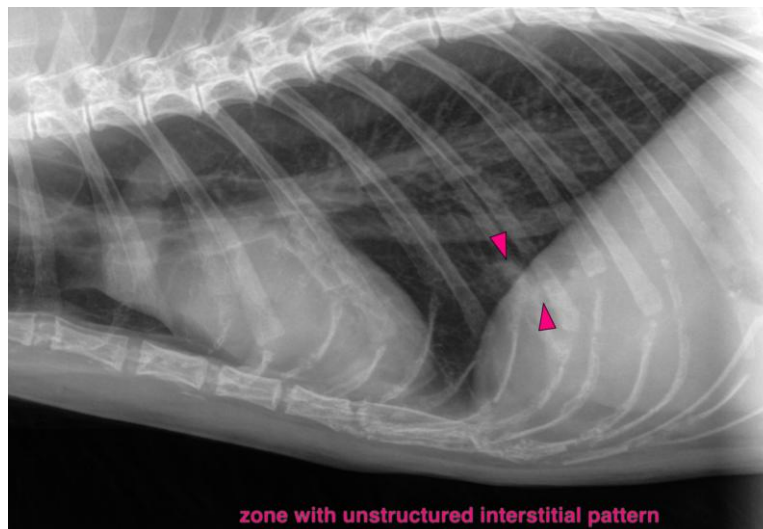
RADIOGRAPHIC DIAGNOSIS

- Zone with unstructured interstitial to alveolar pattern ventral aspect left caudal lung lobe
- Mild nephrolithiasis
- Spondylosis deformans

INTERPRETATION OF THE FINDINGS & FURTHER RECOMMENDATIONS

Due to the nearly stationary finding, the odds for benign origin of the zone with an unstructured interstitial pattern are very high – such as chronic pneumonia, fibrosis or atelectasis.

The abdomen reveals no clinically relevant abnormalities.



The information and recommendations provided are based on the images presented by the referring veterinarian/sonographer. No evaluation can be communicated regarding pathology that was not visible in the image/video clips provided.

Thank you for this referral. If the clinical or image interpretation does not parallel your findings or if I can be of any further assistance please contact me.

Sebastian Schaub, Sebastian Schaub, DVM, Dr. med. vet. DipECVDI
info@sonopath.com