



PATIENT

Kiko Costa

SPECIES

Canine

BREED

Ridgeback Mix

SEX

Male Neutered

AGE

13Y, 6M

WEIGHT

23.9kg

INTERPRETED BY

Sebastian Schaub, DVM
Dr. med. vet.
DipECVDI

IMAGING PERFORMED BY

Lisa S.

HOSPITAL NAME

Animal Surgical Center
- Oceanside

REFERRING VET

Dr. Infernuso

INVOICE

73520

DATE

1-28-26

PRESENTING CLINICAL SIGNS

History:

- Large pelvic mass palpated rectally on right side
- Heart murmur II/VI

COMPUTED TOMOGRAPHY OF THE THORAX AND ABDOMEN

A high resolution plain CT study of the thorax and abdomen is provided for review.

COMPUTED TOMOGRAPHIC FINDINGS

Thorax

Along the thoracic wall and prescapular region, multiple, variable sized lipomas are seen.

Level with the right thyroid gland, at the lateral aspect of the trachea, a well-defined, ovoid shaped, soft tissue attenuating mass with interspersed fine granular mineralization is visible, measuring 2.9 cm in diameter and 3.8 cm in length.

The sternal, cranial mediastinal and tracheobronchial lymph nodes are small elongated with a normal short-to-long-axis-ratio is < 0.5, the attenuation pattern is uniform.

The cardiovascular structures including the pulmonary vasculature are within normal limits.

The bronchial tree presents with regular branching and tapers uniformly towards the periphery as expected, the bronchial walls are thin and smooth. The bronchus-to-artery ratio is within normal limits.

Throughout the lung parenchyma, sporadic, soft tissue attenuating nodules are seen; measuring ≤ 4 mm in diameter.

Small incidental gas pockets are seen within the esophageal lumen; there is no evidence of abnormal dilation.

Abdomen

The serosal fat presents normal attenuation behavior. There is no evidence of peritoneal effusion or peritonitis.

Both kidneys present within normal limits for size, shape and organ architecture. A urinary catheter is visible in the bladder.

The adrenal glands are within normal limits for size, shape and organ architecture.

Both liver and spleen present with normal shape, even surface, uniformly attenuating parenchyma and homogeneous contrast enhancement, unremarkable.

The pancreas is evenly contoured; the pancreatic parenchyma is homogeneous.

The position, delineation, wall and content of the gastrointestinal tract are considered within normal limits throughout.

In the dorsal aspect of the pelvic canal, ventral to the sacrum and Cg1 & Cg 2 an irregular ovoid shaped, soft tissue attenuating mass with focal mineralization is seen; measuring approximately 6.2 x 9.2 x 6.3 cm occupying approximately 95% of the cross-sectional area of the pelvic canal – the colon/rectum and urethra are deviated ventrally and are compressed. The first right ventral sacral foramen is significantly widened and the ventral cortex of the sacrum being in contact with the mass presents a rough surface



PATIENT

Kiko Costa

SPECIES

Canine

BREED

Ridgeback Mix

SEX

Male Neutered

AGE

13Y, 6M

WEIGHT

23.9kg

INTERPRETED BY

Sebastian Schaub, DVM
Dr. med. vet.
DipECVDI

IMAGING PERFORMED BY

Lisa S.

HOSPITAL NAME

Animal Surgical Center
- Oceanside

REFERRING VET

Dr. Infernuso

INVOICE

73520

DATE

1-28-26

with moth eaten defects. Along the lateral surface of the right iliac wind rough solid periosteal new bone formation is seen.

The right internal iliac lymph node is prominent and hyperattenuating.

COMPUTED TOMOGRAPHIC DIAGNOSIS

- Soft tissue mass dorsal aspect of pelvic canal with pressure erosion of the right first ventral sacral foramen and semiaggressive osteolytic lesions of the ventral cortex of the sacrum – secondary compression of the colon and urethra
- Hyperattenuating lymphadenopathy right internal iliac lymph node
- Right thyroid soft tissue mass with dystrophic mineralization
- Structured nodular interstitial lung pattern

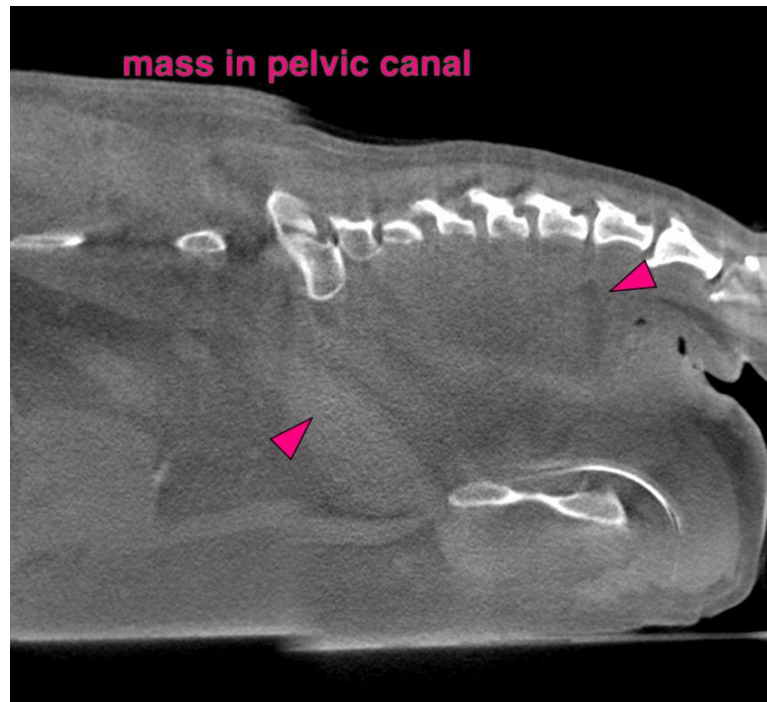
INTERPRETATION OF THE FINDINGS & FURTHER RECOMMENDATIONS

The soft tissue mass in the pelvic canal is compatible with soft tissue neoplasia – such as sarcoma or metastasis of an anal sac adenocarcinoma. FNA sampling may be performed for specification.

The enlarged and mild hyperattenuating right internal iliac lymph node is highly suggestive for metastatic spread.

The right thyroid soft tissue mass is most consistent with a second entity and thyroid carcinoma is most likely.

The pulmonary nodules are indicative for pulmonary metastatic spread.





PATIENT

Kiko Costa

SPECIES

Canine

BREED

Ridgeback Mix

SEX

Male Neutered

AGE

13Y, 6M

WEIGHT

23.9kg

INTERPRETED BY

Sebastian Schaub, DVM
Dr. med. vet.
DipECVDI

IMAGING PERFORMED BY

Lisa S.

HOSPITAL NAME

Animal Surgical Center
- Oceanside

REFERRING VET

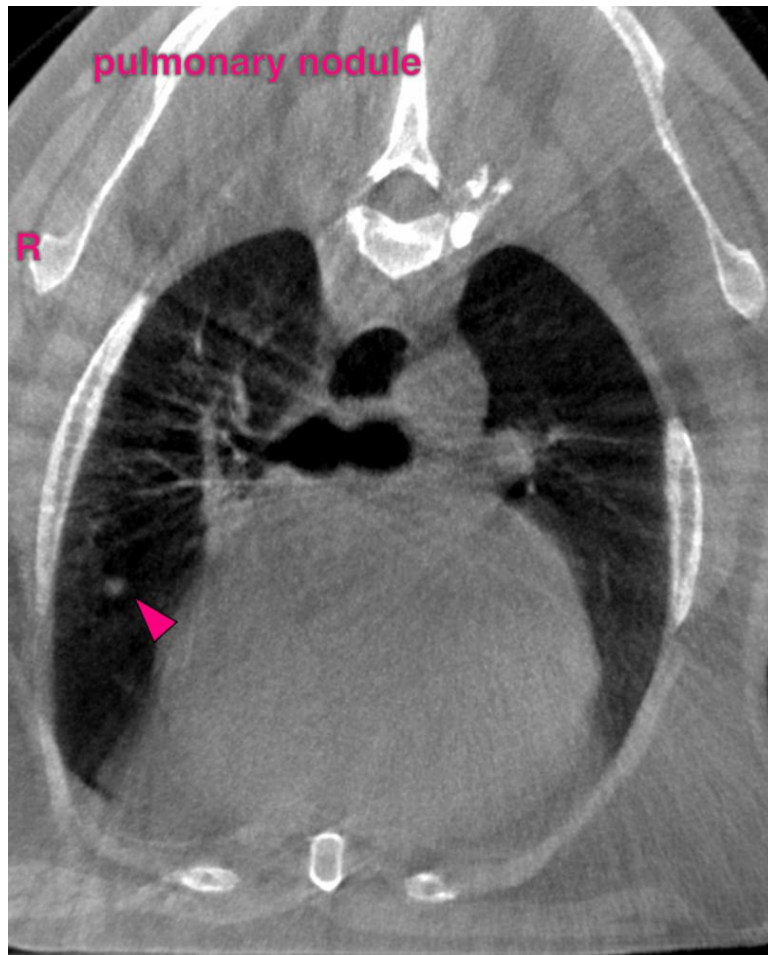
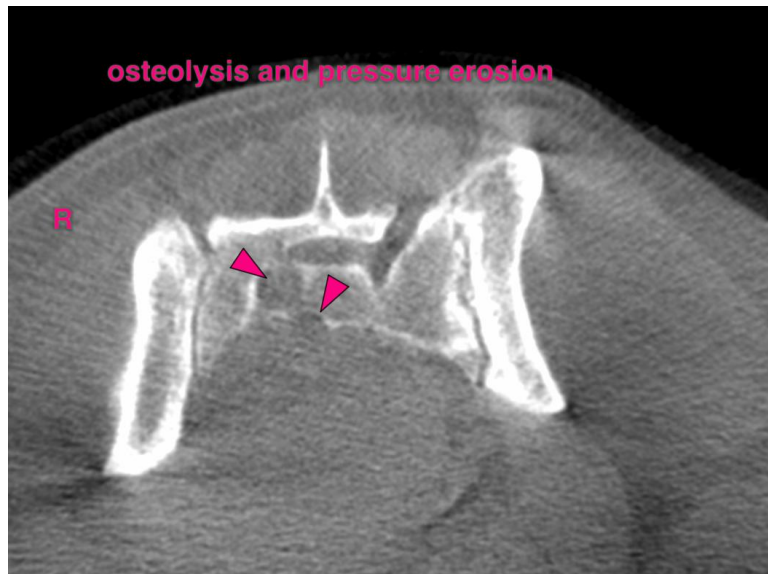
Dr. Infernuso

INVOICE

73520

DATE

1-28-26





PATIENT

Kiko Costa

SPECIES

Canine

BREED

Ridgeback Mix

SEX

Male Neutered

AGE

13Y, 6M

WEIGHT

23.9kg

INTERPRETED BY

Sebastian Schaub, DVM
Dr. med. vet.
DipECVDI

IMAGING PERFORMED BY

Lisa S.

HOSPITAL NAME

Animal Surgical Center
- Oceanside

REFERRING VET

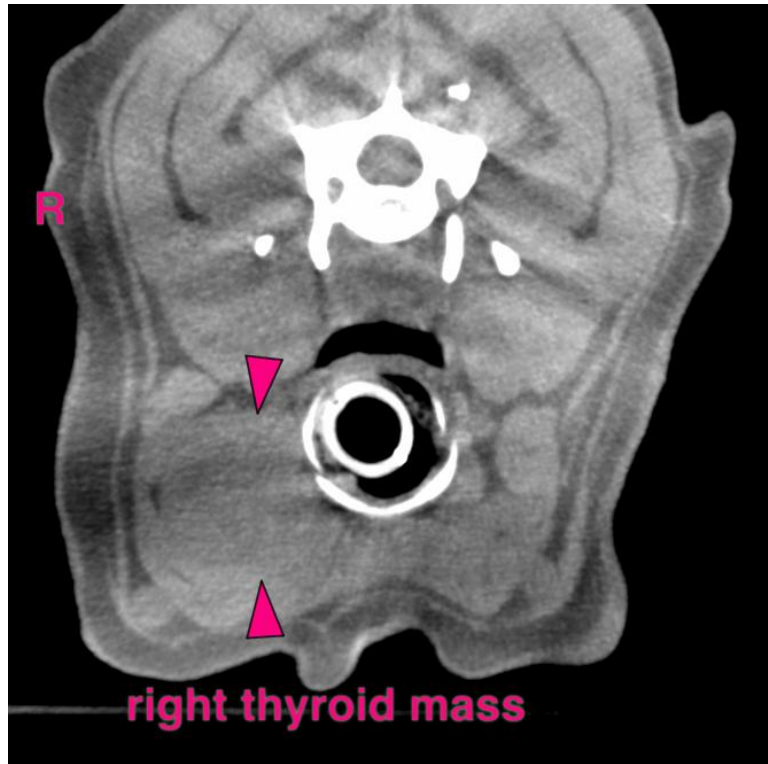
Dr. Inferuso

INVOICE

73520

DATE

1-28-26



The information and recommendations provided are based on the images presented by the referring veterinarian/sonographer. No evaluation can be communicated regarding pathology that was not visible in the image/video clips provided.

Thank you for this referral. If the clinical or image interpretation does not parallel your findings or if I can be of any further assistance please contact me.

Sebastian Schaub, Sebastian Schaub, DVM, Dr. med. vet. DipECVDI
info@sonopath.com