



PATIENT

Leo Lyle

PRESENTING CLINICAL SIGNS

Yesterday Leo ran out of the front door and slipped on the Ice. His feet went one way and his back the other day. He is having trouble getting up and moving around. He has been panting a lot and he is shakey. Cindy thinks the right hip area looks swollen and puffed out.

SPECIES

Canine

Abnormal PE/Chem/CBC/UA Results: BILATERAL STIFLE MEDIAL BUTTRESS RIGHT HIND, CRANIAL AND DORSAL TO TUBER ISCHII Ambulatory X 4, 3/5 RIGHT HIND LAME

BREED

Labrador Retriever Mix

RADIOGRAPHIC STUDY OF THE PELVIS

Radiographs of the pelvis in two orthogonal imaging planes are provided for review.

RADIOGRAPHIC FINDINGS

The osseous and surrounding soft tissue structures of the pelvis are within normal limits. The coxofemoral joints present with congruent joint spaces.

SEX

MN

The volume of the right thigh musculature is moderately decreased in comparison to the left side.

AGE

5 Years, 9 Months

RADIOGRAPHIC DIAGNOSIS

- Normal pelvis
- Disuse atrophy musculature right hind limb

INTERPRETATION OF THE FINDINGS & FURTHER RECOMMENDATIONS

The radiographic study of the pelvis/coxofemoral joints presents without abnormalities, but the disuse atrophy of the musculature. Rule out acute on chronic disease – advanced degenerative joint disease of the stifle joints.

HOSPITAL NAME

Elizabeth Animal Hospital

REFERRING VET

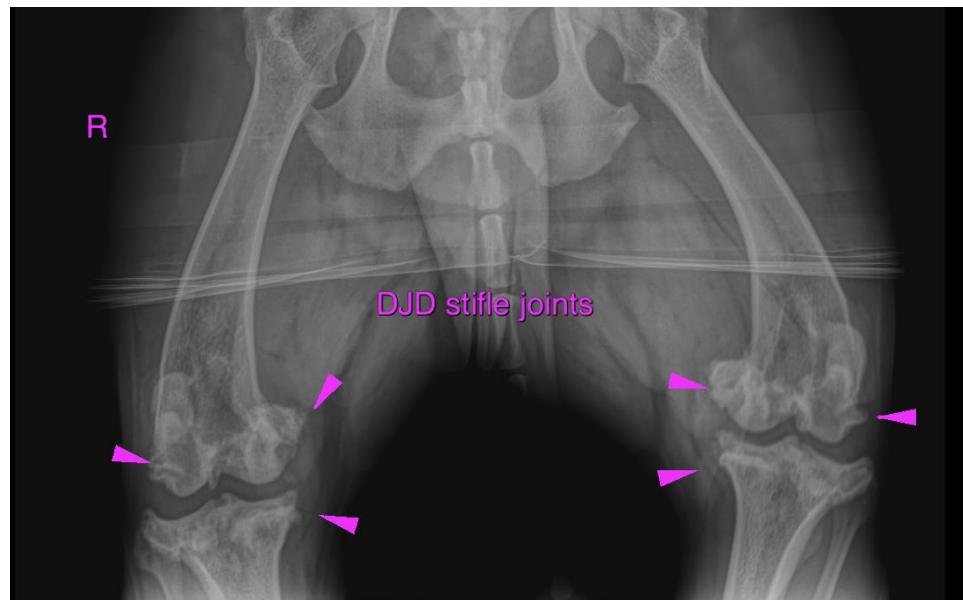
Leon Anderson, DVM

INVOICE

49940

DATE

1-28-22





PATIENT

Leo Lyle

The information and recommendations provided are based on the images presented by the referring veterinarian/sonographer. No evaluation can be communicated regarding pathology that was not visible in the image/video clips provided.

SPECIES

Canine

Thank you for this referral. If the clinical or image interpretation does not parallel your findings or if I can be of any further assistance please contact me.

BREED

Labrador Retriever
Mix

Sebastian Schaub, Sebastian Schaub, DVM, Dr. med. vet. DipECVDI
sebast.schaub@gmail.com

SEX

MN

AGE

5 Years, 9 Months

INTERPRETED BY

Sebastian Schaub, DVM
Dr. med. vet. DipECVDI

HOSPITAL NAME

Elizabeth Animal
Hospital

REFERRING VET

Leon Anderson, DVM

INVOICE

49940

DATE

1-28-22