



PATIENT

Rush Smallberg

SPECIES

Canine

BREED

Doberman Pinscher

SEX

Male Neutered

AGE

9Y, 6M

WEIGHT

29kg

INTERPRETED BY

Sebastian Schaub, DVM
Dr. med. vet.
DipECVDI

IMAGING PERFORMED BY

Lisa S.

HOSPITAL NAME

Animal Surgical Center
- Oceanside

REFERRING VET

Dr. Infernuso

INVOICE

73497

DATE

1-27-26

PRESENTING CLINICAL SIGNS

History:

- history of metastatic disease from a melanoma removed from the neck
- increased respiratory noises
- Melanoma removed History (2024)

COMPUTED TOMOGRAPHY OF THE NECK, THORAX AND ABDOMEN

A high resolution pre- and post-contrast CT study of the neck and abdomen and a post-contrast CT study of the thorax is provided for review.

COMPUTED TOMOGRAPHIC FINDINGS

Neck

The submandibular and medial retropharyngeal lymph nodes are small and elongated with a normal short-to-long-axis-ratio is < 0.5 , the attenuation and contrast enhancement pattern is uniform.

The thyroid glands present the expected size, shape and attenuation behavior.

The osseous and soft tissue structures of the neck are within normal limits.

Thorax

The bony and surrounding soft tissue structures are within normal limits.

The sternal, cranial mediastinal and tracheobronchial lymph nodes are small elongated with a normal short-to-long-axis-ratio is < 0.5 , the attenuation and contrast enhancement pattern is uniform and considered within normal limits.

The cardiovascular structures including the pulmonary vasculature are within normal limits.

In the cranial aspect of the left caudal lung lobe, a roundish, uniform soft tissue attenuating mild irregular contrast enhancing mass is seen; measuring approximately 7 cm in diameter. The mass in the left cranial lung lobe is encompassing and distorting the first degree bronchus. The remainder of the lung parenchyma are aerated and present the expected architecture.

Small incidental gas pockets are seen within the esophageal lumen; there is no evidence of abnormal dilation.

Abdomen

The serosal fat presents normal attenuation behavior. There is no evidence of peritoneal effusion or peritonitis.

Both kidneys present within normal limits for size, shape and organ architecture. After contrast administration, a bilaterally symmetric and uniform nephro- and pyelogram is noted.

Due to the limited contrast and streak artefacts, the adrenal glands cannot be delineated.

Both liver and spleen present with normal shape, even surface, uniformly attenuating parenchyma and homogeneous contrast enhancement, unremarkable.

The position, delineation, wall and content of the gastrointestinal tract are considered within normal limits throughout.



PATIENT

Rush Smallberg

SPECIES

Canine

BREED

Doberman Pinscher

SEX

Male Neutered

AGE

9Y, 6M

WEIGHT

29kg

INTERPRETED BY

Sebastian Schaub, DVM
Dr. med. vet.
DipECVDI

IMAGING PERFORMED BY

Lisa S.

HOSPITAL NAME

Animal Surgical Center
- Oceanside

REFERRING VET

Dr. Inferuso

INVOICE

73497

DATE

1-27-26

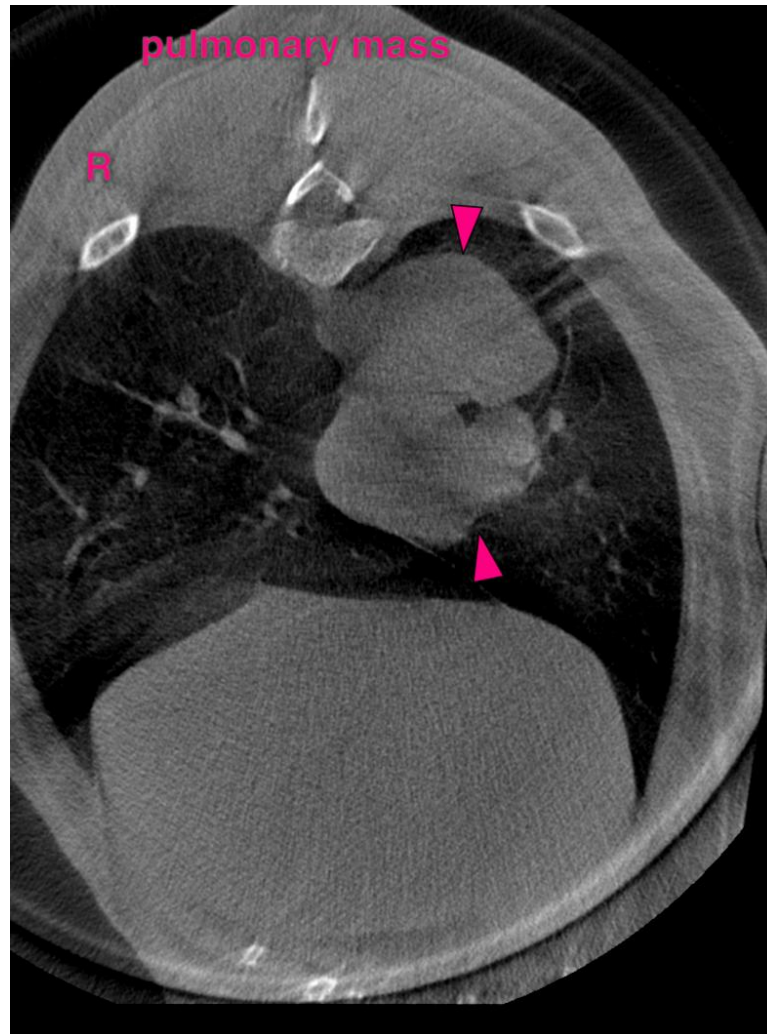
The bony and surrounding soft tissue structures reveal no abnormalities.

COMPUTED TOMOGRAPHIC DIAGNOSIS

- Solitary pulmonary peribronchial pulmonary mass left caudal lung lobe
- No evidence of pulmonary metastatic disease
- Normal appearing abdomen
- Normal appearing neck

INTERPRETATION OF THE FINDINGS & FURTHER RECOMMENDATIONS

The pulmonary mass is most suggestive for primary pulmonary soft tissue neoplasia – such as carcinoma – I consider the odds for pulmonary metastatic disease of the excised melanoma low. Complete surgical excision of the pulmonary mass is considered feasible.





PATIENT

Rush Smallberg

SPECIES

Canine

BREED

Doberman Pinscher

SEX

Male Neutered

AGE

9Y, 6M

WEIGHT

29kg

INTERPRETED BY

Sebastian Schaub, DVM
Dr. med. vet.
DipECVDI

IMAGING PERFORMED BY

Lisa S.

HOSPITAL NAME

Animal Surgical Center
- Oceanside

REFERRING VET

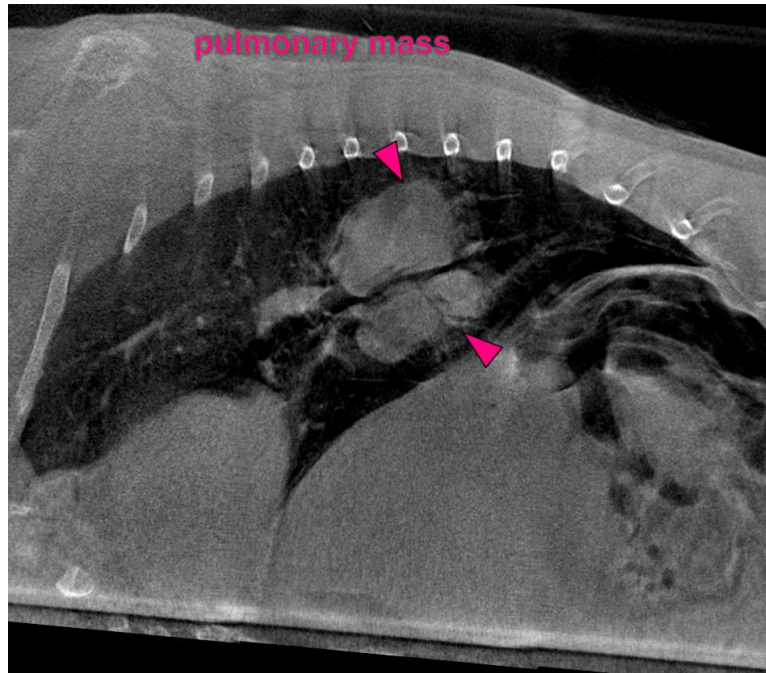
Dr. Infernuso

INVOICE

73497

DATE

1-27-26



The information and recommendations provided are based on the images presented by the referring veterinarian/sonographer. No evaluation can be communicated regarding pathology that was not visible in the image/video clips provided.

Thank you for this referral. If the clinical or image interpretation does not parallel your findings or if I can be of any further assistance please contact me.

Sebastian Schaub, Sebastian Schaub, DVM, Dr. med. vet. DipECVDI
info@sonopath.com