



PATIENT PRESENTING CLINICAL SIGNS

Ruger Adams History: History of CHF, Grade 5 heart murmur, coughing

RADIOGRAPHIC STUDY OF THE THORAX

SPECIES

Canine Radiographs of the thorax in three imaging planes are provided for review. Radiographs are provided in JPEG file format.

RADIOGRAPHIC FINDINGS

BREED

Papillon The body condition score is 7/9.

The surrounding bony structures are within normal limits.

SEX

Male A well-defined ovoid shaped mineral opaque body is seen in the subcutaneous tissue dorsal to the spinous process of T2

Male

AGE

13 Years The caudal contour of the cardiac silhouette is steep and the caudal cardiac waist is lost. A wedge shaped soft tissue opacity is seen in the region of the left atrium; in the VD projection, abaxial splaying of the main-stem bronchi is seen as well as a double opacity in the region of the left atrium.

The cranial mediastinum presents the expected soft tissue opacity. The mediastinal width is less than twice the width of the vertebral column at the same level.

INTERPRETED BY

Sebastian Schaub,
DVM Dr. med. vet.
DipECVDI

The trachea is normal in diameter and presents the anticipated course. The luminal outline of the trachea is smooth.

The lung parenchyma has a generalized moderate ground glass opacity, caused by an unstructured reticular pattern. The pulmonary vasculature is partially effaced by the lung pattern, the pulmonary veins appear prominent.

HOSPITAL NAME

Mt. Yonah AH

The diaphragm is well delineated with even surface and the expected mild cranial bulging of the diaphragmatic cupola.

REFERRING VET

Ashley Douglass,
DVM

RADIOGRAPHIC DIAGNOSIS

- Left sided cardiomegaly
- Generalized unstructured interstitial lung pattern
- Suspect prominent pulmonary veins
- Subcutaneous nodular fat necrosis dorsal to the cranial thoracic spine

INVOICE

20820

INTERPRETATION OF THE FINDINGS & FURTHER RECOMMENDATIONS

DATE

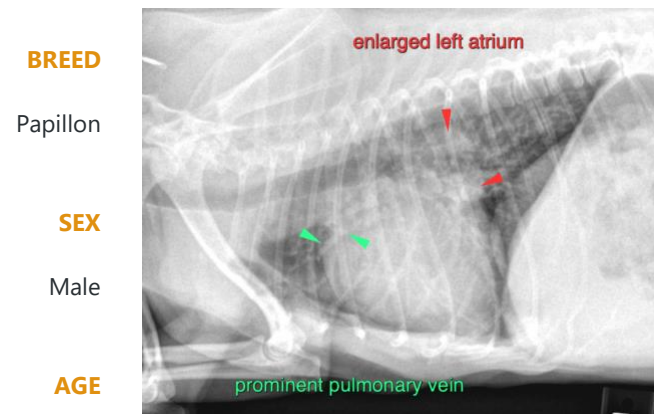
1/27/23



PATIENT Ruger Adams
 The left sided cardiomegaly is fitting the history of possible underlying mitral valve insufficiency and secondary left cardiac volume overload. The unstructured interstitial lung pattern in combination with the prominent pulmonary veins is most suggestive for cardiogenic pulmonary edema.

Mechanical interaction of the left atrium with the principal bronchi can induce cough as well.

SPECIES Canine
 Other differentials for the interstitial lung pattern include fibrosis, pneumonitis (inflammatory versus infectious), systemic disease (e.g. pancreatitis, IMHA, renal disease), neoplasia.



The information and recommendations provided are based on the images presented by the referring veterinarian/sonographer. No evaluation can be communicated regarding pathology that was not visible in the image/video clips provided.

INTERPRETED BY Sebastian Schaub, DVM Dr. med. vet. DipECVDI
 Thank you for this referral. If the clinical or image interpretation does not parallel your findings or if I can be of any further assistance please contact me.

HOSPITAL NAME Mt. Yonah AH

Sebastian Schaub, Sebastian Schaub, DVM, Dr. med. vet. DipECVDI
 sebast.schaub@gmail.com

REFERRING VET

Ashley Douglass, DVM

INVOICE

20820

DATE

1/27/23