



**PATIENT PRESENTING CLINICAL SIGNS**

Levi Hill History: This dog had FHO in LH 3 weeks ago . He still non-weight bearing on LH  
Abnormal PE/Chem/CBC/UA Results: N/A

**SPECIES RADIOGRAPHIC STUDY OF THE PELVIS AND LEFT STIFLE JOINT**

Canine A ventrodorsal view of the pelvis and a mediolateral and craniocaudal view of the left stifle joint is provided for review.

**BREED RADIOGRAPHIC FINDINGS**

Flat Coated Retriever Mix The osseous structures of the pelvis are within normal limits. The volume of the soft tissue shadow of the musculature of the left hind limb is significantly decreased. The left femoral head is absent. A short stump of the left femoral neck with rounded margins is appreciated. The left femur in a relative proximal position in comparison to the right femur.

**SEX**

Neutered Male The left stifle joint has smooth osseous margins of the periarticular bones and there is no evidence of an intracapsular soft tissue swelling.

**AGE RADIOGRAPHIC DIAGNOSIS**

- 2 Years
- History of left sided femoral head ostectomy – a short remaining stump of the femoral head is present
  - Advanced disuse atrophy musculature left hind limb
  - Normal left stifle joint

**INTERPRETED BY**

Sebastian Schaub,  
DVM Dr. med. vet.  
DipECVDI

**INTERPRETATION OF THE FINDINGS & FURTHER RECOMMENDATIONS**

The radiographic study presents without abnormalities of the left stifle joint, increasing the odds that the lameness is originating from the surgery site. The remaining stump of the femoral head might still impinge on the acetabulum, causing pain. Check if normal neural function of the left sciatic nerve as well.

**HOSPITAL NAME**

St. Catherine's AH

**REFERRING VET**

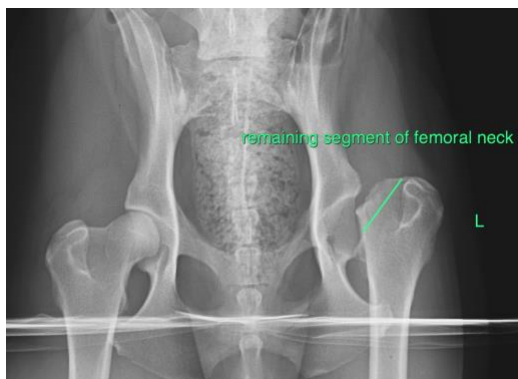
Dr. Boctor

**INVOICE**

20825

**DATE**

1/27/23





**PATIENT** The information and recommendations provided are based on the images presented by the referring veterinarian/sonographer. No evaluation can be communicated regarding pathology that was not visible in the image/video clips provided.

Levi Hill

Thank you for this referral. If the clinical or image interpretation does not parallel your findings or if I can be of any further assistance please contact me.

**SPECIES**

Canine

**Sebastian Schaub**, Sebastian Schaub, DVM, Dr. med. vet. DipECVDI  
sebast.schaub@gmail.com

**BREED**

Flat Coated Retriever  
Mix

**SEX**

Neutered Male

**AGE**

2 Years

**INTERPRETED BY**

Sebastian Schaub,  
DVM Dr. med. vet.  
DipECVDI

**HOSPITAL NAME**

St. Catherine's AH

**REFERRING VET**

Dr. Boctor

**INVOICE**

20825

**DATE**

1/27/23