



PATIENT PRESENTING CLINICAL SIGNS

PATIENT Gracie Murphy
SPECIES Canine
BREED English Cream Retriever
SEX Spayed Female
AGE 6 Years 8 Months

History: Owner noticed a dry cough and brought Gracie in for an exam on 1/4. She was treated for allergic bronchitis with temaril P with initial improvement but then the coughing came back. X-rays were taken at this time and temaril P was switched to prednsione and zeniquin was added. Gracie's cough again improved but returned when tapered from BID to SID steroids. Gracie has also had some audible nasal congestion and discharge. Eating and drinking normally.

RADIOGRAPHIC STUDY OF THE THORAX

Radiographs of the thorax in three imaging planes are provided for review. Radiographs are dated 1/17/23.

RADIOGRAPHIC FINDINGS

The surrounding bony structures are within normal limits.

The extrathoracic soft tissues present homogeneous without abnormalities.

The heart is of normal size and shape, there is no evidence of cardiac chamber or vascular enlargement. The pulmonary vasculature is within normal limits.

The cranial mediastinum presents the expected soft tissue opacity. The mediastinal width is less than twice the width of the vertebral column at the same level.

The trachea is normal in diameter and presents the anticipated course. The luminal outline of the trachea is smooth.

Most accentuated the ventral dependent aspects of the lung present multifocal peribronchial cuffing and zones with pulmonary consolidation with air-bronchograms.

The diaphragm is well delineated with even surface and the expected mild cranial bulging of the diaphragmatic cupola.

RADIOGRAPHIC DIAGNOSIS

- Ventrally distributed peripheral zones with alveolar pattern and bronchial pattern

INTERPRETATION OF THE FINDINGS & FURTHER RECOMMENDATIONS

The pulmonary pattern is suggestive for bacterial broncho-pneumonia. Given the upper respiratory clinical signs, rule out upper airway disease as trigger for the broncho-pneumonia.

INVOICE

20829

DATE

1/27/23

INTERPRETED BY

Sebastian Schaub,
 DVM Dr. med. vet.
 DipECVDI

HOSPITAL NAME

Gentle Doctor AH

REFERRING VET

Dr. Rotthaus



PATIENT

Gracie Murphy

SPECIES

Canine

BREED

English Cream
Retriever

SEX

Spayed Female

AGE

6 Years 8 Months

INTERPRETED BY

Sebastian Schaub,
DVM Dr. med. vet.
DipECVDI

HOSPITAL NAME

Gentle Doctor AH

REFERRING VET

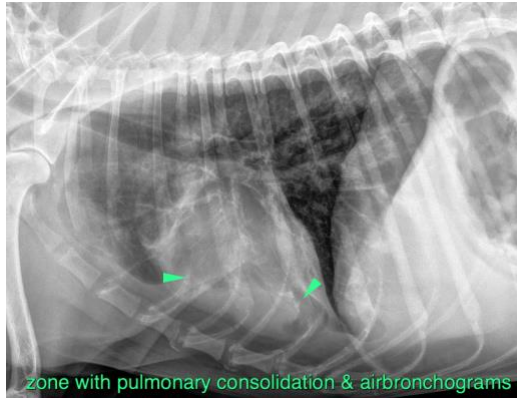
Dr. Rotthaus

INVOICE

20829

DATE

1/27/23



The information and recommendations provided are based on the images presented by the referring veterinarian/sonographer. No evaluation can be communicated regarding pathology that was not visible in the image/video clips provided.

Thank you for this referral. If the clinical or image interpretation does not parallel your findings or if I can be of any further assistance please contact me.

Sebastian Schaub, Sebastian Schaub, DVM, Dr. med. vet. DipECVDI
sebast.schaub@gmail.com