



PATIENT

Theo Zenelaj

PRESENTING CLINICAL SIGNS

Theo is a 14-month-old neutered male English Bulldog presented for weight loss and lethargy over the past 3 months. On the exam an abdominal mass was palpated and he was painful on palpation. His blood work 2 weeks ago revealed a moderate non-regenerative anemia. He has lost almost 9 lbs over the past 5 months.

SPECIES

Canine

RADIOGRAPHIC STUDY OF THE ABDOMEN

A radiographic study of the abdomen in three imaging planes is provided for review.

BREED

Bulldog, English

RADIOGRAPHIC FINDINGS

The surrounding bony structures are within normal limits.

SEX

Neutered Male

No abnormalities of the extraabdominal soft tissues are noted. The abdominal wall is smooth and thin.

The craniodorsal aspect of the abdomen, a large soft tissue opaque, ill-defined space occupying lesion visible, displacing the small intestinal loops ventrally and the stomach mildly cranially.

AGE

14 Months

One kidney is displaced caudally by the mass effect.

The liver is appropriate in position, size and presents uniform opacity.

INTERPRETED BY

Sebastian Schaub, DVM
Dr. med. vet. DipECVDI

The splenic head is in the anticipated position and within normal limits for size and opacity. The splenic body and tail are considered normal for position, size, shape and opacity.

RADIOGRAPHIC DIAGNOSIS

- Large cranial retroperitoneal soft tissue mass

HOSPITAL NAME

Beaches-Fallingbrook
Veterinary Clinic

INTERPRETATION OF THE FINDINGS & FURTHER RECOMMENDATIONS

The origin of the large craniodorsal abdominal mass cannot be specified, and potentials include neoplasia from the connective tissues/musculature, kidney, lymph node, adrenal gland; hematoma, abscess. A complete abdominal ultrasound examination has already been performed for further definition. CT study might allow further evaluation of the involved retroperitoneal/abdominal structures.

REFERRING VET

Dr. Matt Haight

INVOICE

49900

DATE

1-27-22



PATIENT

Theo Zenelaj

SPECIES

Canine

BREED

Bulldog, English

SEX

Neutered Male

AGE

14 Months

INTERPRETED BY

Sebastian Schaub, DVM
Dr. med. vet. DipECVDI

HOSPITAL NAME

Beaches-Fallingbrook
Veterinary Clinic

REFERRING VET

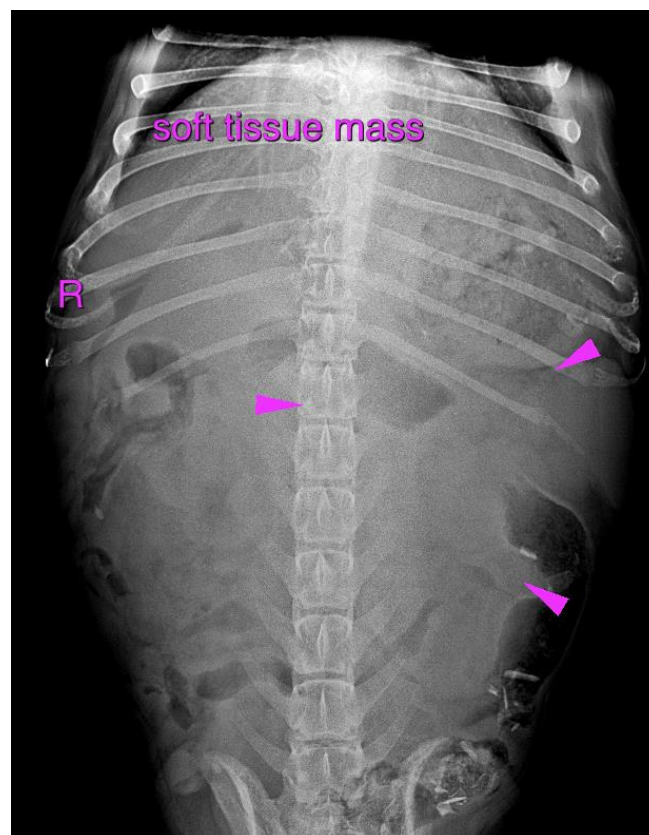
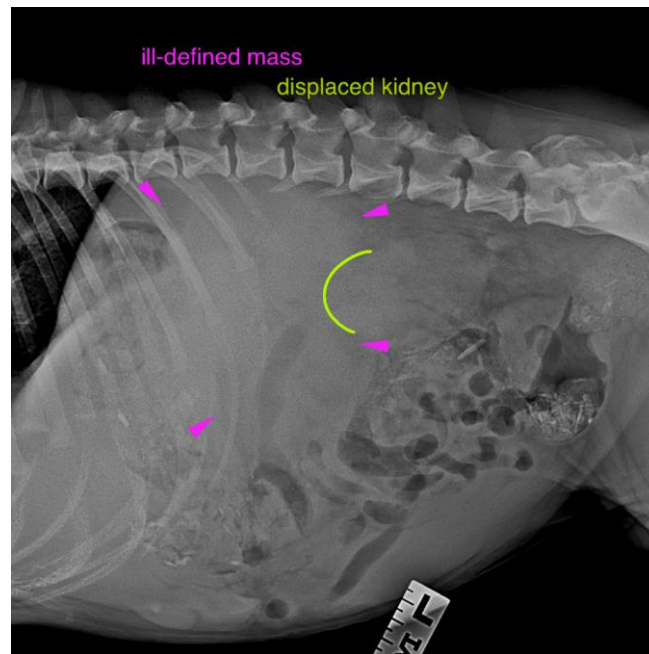
Dr. Matt Haghighat

INVOICE

49900

DATE

1-27-22





PATIENT

Theo Zenelaj

SPECIES

Canine

BREED

Bulldog, English

SEX

Neutered Male

AGE

14 Months

INTERPRETED BY

Sebastian Schaub, DVM
Dr. med. vet. DipECVDI

HOSPITAL NAME

Beaches-Fallingbrook
Veterinary Clinic

REFERRING VET

Dr. Matt Haight

INVOICE

49900

DATE

1-27-22

The information and recommendations provided are based on the images presented by the referring veterinarian/sonographer. No evaluation can be communicated regarding pathology that was not visible in the image/video clips provided.

Thank you for this referral. If the clinical or image interpretation does not parallel your findings or if I can be of any further assistance please contact me.

Sebastian Schaub, Sebastian Schaub, DVM, Dr. med. vet. DipECVDI
sebast.schaub@gmail.com