



PATIENT

Piper Adams

PRESENTING CLINICAL SIGNS

Diagnosed with anal gland AGASACA. Scanned performed to rule out metastatic spread to abdominal lymph nodes.

SPECIES

Canine

COMPUTED TOMOGRAPHY OF THE PELVIS

A high resolution pre- and post-contrast CT study of the pelvis is provided for review.

BREED

Dachshund

COMPUTED TOMOGRAPHIC FINDINGS

A roundish, post contrast multiloculated mass is originating from the left anal sac, measuring 2.3 x 3.0 x 2.7 cm in size. A small roundish mineralization is seen in the ventral aspect of the mass. The rectum is mildly distorted by the mass effect.

SEX

MN

The right anal sac is unremarkable.

The hypogastric lymph nodes are within normal limits.

The pictured parts of the abdomen are unremarkable.

AGE

9 Years

The bony and surrounding soft tissue structures reveal no abnormalities.

INTERPRETED BY

Sebastian Schaub, DVM
Dr. med. vet. DipECVDI

- History of left sided anal sac adenocarcinoma

INTERPRETATION OF THE FINDINGS & FURTHER RECOMMENDATIONS

The CT study is negative for macroscopic metastatic spread to the tributary lymph nodes.

HOSPITAL NAME

Southern Oregon
Veterinary Specialty
Center

REFERRING VET

Dr. Fugazzi

INVOICE

49918

DATE

1-27-22



PATIENT

Piper Adams

SPECIES

Canine

BREED

Dachshund

SEX

MN

AGE

9 Years

INTERPRETED BY

Sebastian Schaub, DVM
Dr. med. vet. DipECVDI

HOSPITAL NAME

Southern Oregon
Veterinary Specialty
Center

REFERRING VET

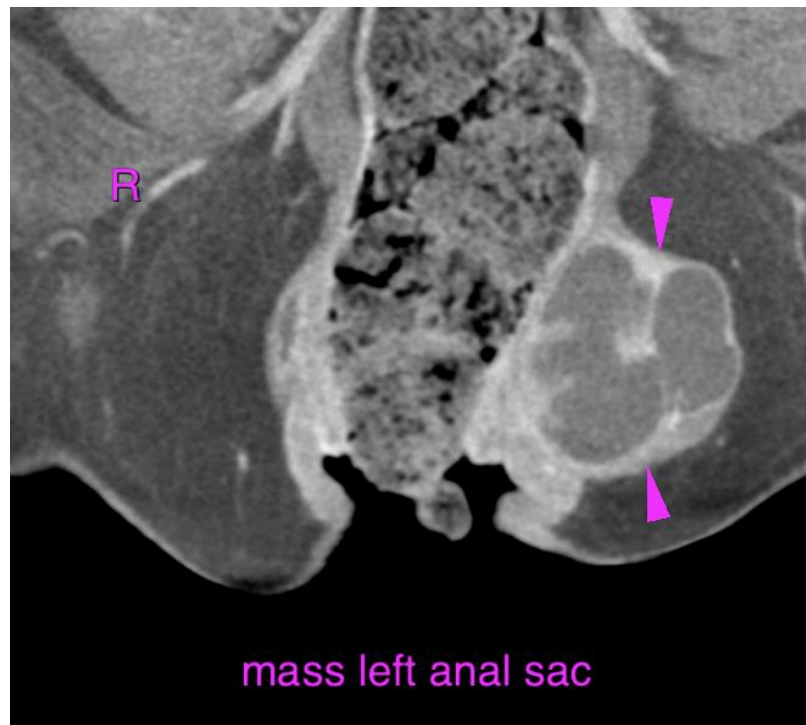
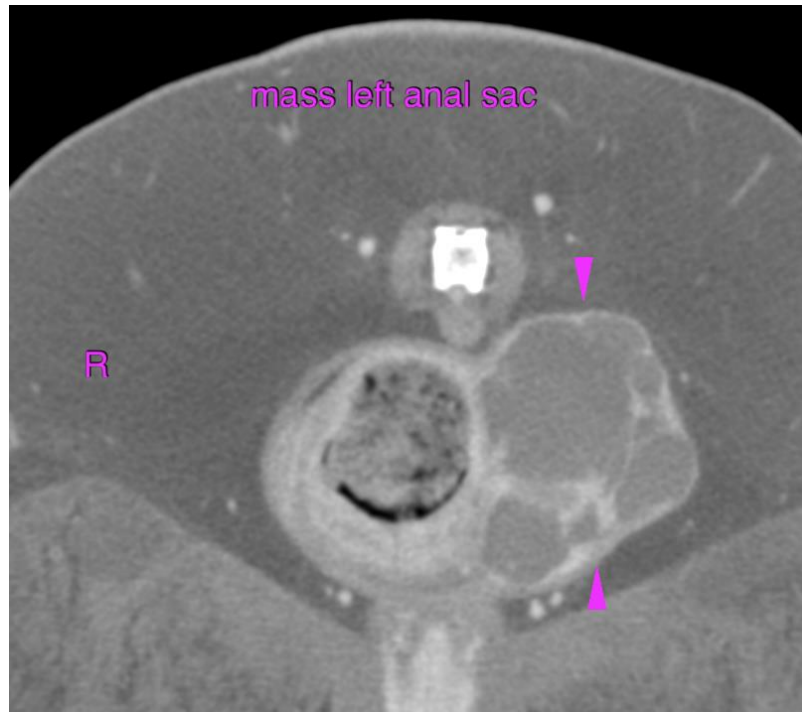
Dr. Fugazzi

INVOICE

49918

DATE

1-27-22





PATIENT

Piper Adams

SPECIES

Canine

BREED

Dachshund

SEX

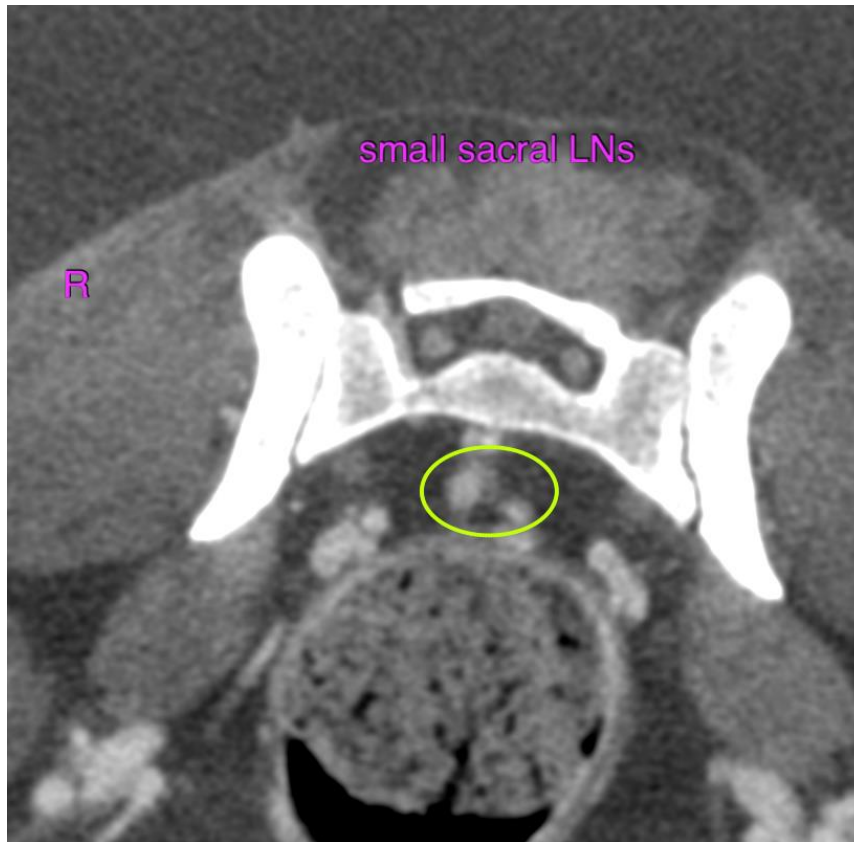
MN

AGE

9 Years

INTERPRETED BY

Sebastian Schaub, DVM
Dr. med. vet. DipECVDI



HOSPITAL NAME

Southern Oregon
Veterinary Specialty
Center

REFERRING VET

Dr. Fugazzi

INVOICE

49918

DATE

1-27-22

The information and recommendations provided are based on the images presented by the referring veterinarian/sonographer. No evaluation can be communicated regarding pathology that was not visible in the image/video clips provided.

Thank you for this referral. If the clinical or image interpretation does not parallel your findings or if I can be of any further assistance please contact me.

Sebastian Schaub, Sebastian Schaub, DVM, Dr. med. vet. DipECVDI
sebast.schaub@gmail.com