



PATIENT PRESENTING CLINICAL SIGNS

Ellie Soloman
 Congestion/Sneezing
 Abnormal PE/Chem/CBC/UA Results: sedated by rDVM prior to our arrival

SPECIES COMPUTED TOMOGRAPHY OF THE SKULL

Feline
 A high resolution pre- and post-contrast CT study of the skull is provided for review.

COMPUTED TOMOGRAPHIC FINDINGS

BREED
 Ocicat
 The tooth elements 106, 206 and 401 are absent.

SEX
 Female Spayed
 The nasal cavity presents the expected aerated spaces between thin & even conchae and turbinates with smooth mucosal lining. A focal mucosal swelling is seen in the caudoventral aspect of the right nasal cavity, and a very mild amount of fluid attenuating material is attached to the nasal mucosal lining in the caudal aspect of both nasal cavities.

AGE
 8 Years
 Both temporomandibular joints present congruent joint spaces with even subchondral bone surfaces and are considered within normal limits.

INTERPRETED BY
 Sebastian Schaub, DVM
 Dr. med. vet. DipECVDI
 The brain presents no deviation from normal anatomy and symmetry. The brain parenchyma is homogeneous and within normal limits for attenuation and distribution of contrast enhancement. The ventricular system is non-dilated and symmetric.

HOSPITAL NAME
 Mobile Pet Imaging
 The submandibular and medial retropharyngeal lymph nodes are small and elongated with a normal short-to-long-axis-ratio is < 0.5, the attenuation and contrast enhancement pattern is uniform.

COMPUTED TOMOGRAPHIC DIAGNOSIS

- REFERRING VET**
 Meaux
- Mild rhinitis
 - Absent triadan 106, 206 and 401
 - No evidence of otitis media or nasopharyngeal polyp

INTERPRETATION OF THE FINDINGS & FURTHER RECOMMENDATIONS

INVOICE
 49893
 The findings present signs for very mild rhinitis with potential mild mucosal hyperplasia. The most likely underlying cause is primary viral. Non-specific rhinitis might be a consideration as well. Rhinoscopy with sampling for microbial culture might be used as advanced diagnostic test. Empirical management is a consideration as well.

DATE

1-27-22



PATIENT

Ellie Soloman

SPECIES

Feline

BREED

Ocicat

SEX

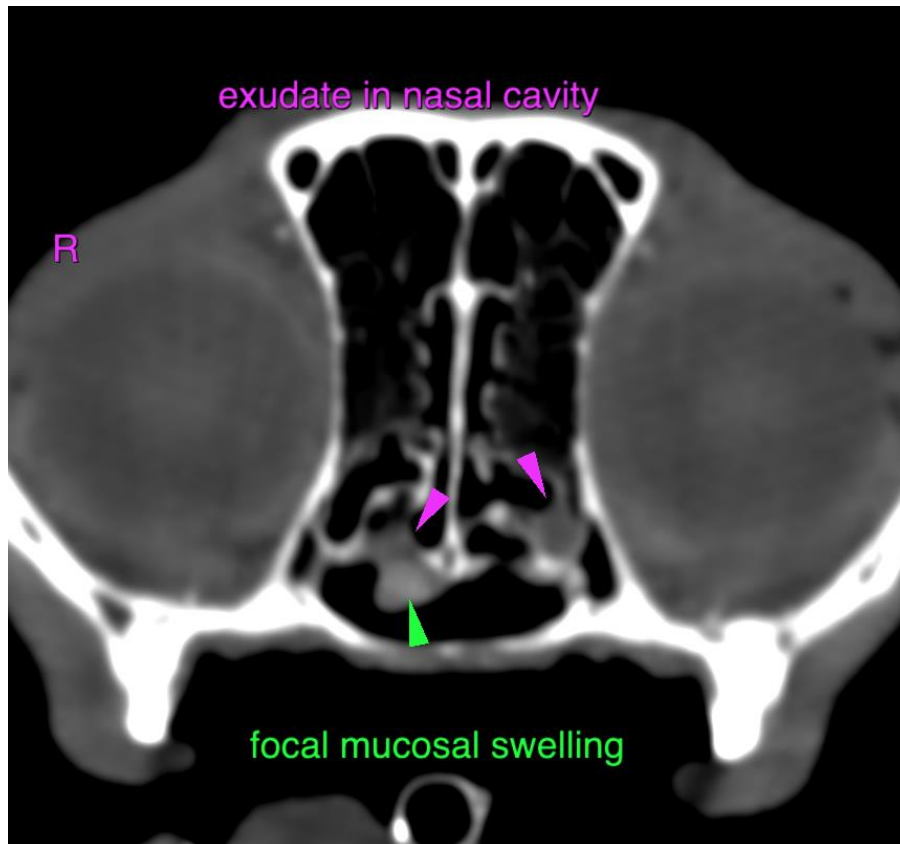
Female Spayed

AGE

8 Years

INTERPRETED BY

Sebastian Schaub, DVM
Dr. med. vet. DipECVDI



HOSPITAL NAME

Mobile Pet Imaging

REFERRING VET

Meaux

INVOICE

49893

DATE

1-27-22

The information and recommendations provided are based on the images presented by the referring veterinarian/sonographer. No evaluation can be communicated regarding pathology that was not visible in the image/video clips provided.

Thank you for this referral. If the clinical or image interpretation does not parallel your findings or if I can be of any further assistance please contact me.

Sebastian Schaub, Sebastian Schaub, DVM, Dr. med. vet. DipECVDI
sebast.schaub@gmail.com