



PATIENT

Mangi Tortop

SPECIES

Canine

BREED

Cotton de tulea

SEX

Male Neutered

AGE

14Y

WEIGHT

6kgs

INTERPRETED BY

Sebastian Schaub, DVM
Dr. med. vet. DipECVDI

IMAGING PERFORMED BY

Mobile Pet Imaging

HOSPITAL NAME

Mobile Pet Imaging

REFERRING VET

Armstrong

INVOICE

73464

DATE

1-26-26

PRESENTING CLINICAL SIGNS

History:

- History of a left adrenal mass and a small caudal mass diagnosed by ultrasound.

Abnormal PE/Chem/CBC/UA Results: PE normal, Vitals wnl

COMPUTED TOMOGRAPHY OF THE THORAX AND ABDOMEN

A high resolution pre- and post-contrast CT study of the abdomen and a post-contrast CT study of the thorax is provided for review.

COMPUTED TOMOGRAPHIC FINDINGS

Thorax

In the subcutaneous tissue multifocal along the thoracic wall, well-defined, lipomas are seen.

The sternal, cranial mediastinal and tracheobronchial lymph nodes are small elongated with a normal short-to-long-axis-ratio is < 0.5, the attenuation and contrast enhancement pattern is uniform and considered within normal limits.

The cardiovascular structures including the pulmonary vasculature are within normal limits.

The bronchial tree presents with regular branching and tapers uniformly towards the periphery as expected, the bronchial walls are thin and smooth. The bronchus-to-artery ratio is within normal limits.

The lung parenchyma presents the expected architecture and attenuation behavior.

Small incidental gas pockets are seen within the esophageal lumen; there is no evidence of abnormal dilation.

Abdomen

The serosal fat presents normal attenuation behavior. There is no evidence of peritoneal effusion or peritonitis.

In the left caudal abdomen, a well-defined, roundish, soft tissue attenuating and mild irregular contrast enhancing mass is seen; presenting multifocal faint interspersed mineralization and measuring 2.4 cm.

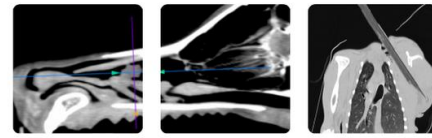
Both kidneys present mild irregular margins. After contrast administration throughout the renal parenchyma, multiple variable sized, well-defined, roundish parenchymal filling defects are seen; measuring up to 5.9 mm in diameter, protruding beyond the renal surface.

The right adrenal gland is within normal limits for size, shape and organ architecture.

Nodular enlargement of the left adrenal gland is appreciated; measuring 1.6 x 1.6 x 2.6 cm. The enlarged left adrenal gland is uniform soft tissue attenuating and has a heterogeneous contrast enhancement pattern.

Both liver and spleen present with normal shape, even surface, uniformly attenuating parenchyma and homogeneous contrast enhancement, unremarkable.

In the gallbladder a moderate amount of mild heterogeneous hyperattenuating gravity dependent sludge is visible.



PATIENT

Mangi Tortop

SPECIES

Canine

BREED

Cotton de tulea

SEX

Male Neutered

AGE

14Y

WEIGHT

6kgs

INTERPRETED BY

Sebastian Schaub, DVM
Dr. med. vet. DipECVDI

IMAGING PERFORMED BY

Mobile Pet Imaging

HOSPITAL NAME

Mobile Pet Imaging

REFERRING VET

Armstrong

INVOICE

73464

DATE

1-26-26

The pancreas is evenly contoured; the pancreatic parenchyma is homogeneous and presents uniform contrast enhancement.

The cardia of the stomach presents an intramural nodule; measuring 12 mm in diameter presenting interspersed granular mineralization. The position, delineation, wall and content of the remainder of the gastrointestinal tract are considered within normal limits throughout.

Level with the intervertebral disc space L4/L5, peripherally mineralized disc material is protruding into the right ventral aspect of the vertebral canal, occupying approximately 15% of the cross-sectional area of the vertebral canal at the same level.

COMPUTED TOMOGRAPHIC DIAGNOSIS

- Nodular enlargement left adrenal gland without vascular invasion
- Peritoneal soft tissue mass left caudal abdomen with dystrophic mineralization
- Small intramural gastric mass with dystrophic mineralization – level with the cardia; the odds for incidental benign leiomyoma are high
- Multiple simple renal cysts
- Intervertebral disc herniation L4/L5 with possible dynamic myelocompression
- Multiple subcutaneous lipomas along the thoracic and abdominal wall
- Biliary sludge without mechanical obstruction
- No evidence of pulmonary metastatic disease

INTERPRETATION OF THE FINDINGS & FURTHER RECOMMENDATIONS

The enlarged left adrenal gland can present (non)functional macronodular hyperplasia versus primary neoplastic transformation of the left adrenal gland (e.g. adenoma, adenocarcinoma, pheochromocytoma). Surgical management is considered feasible.

The peritoneal soft tissue mass in the left caudal abdomen is most suggestive to have a benign origin, such as granuloma or peritoneal leiomyoma. Malignancy such as carcinoma, sarcoma or neoplastic transformation of a cryptorchid testicle (prostate presents no evidence of retained testicle) is considered less likely. Complete surgical excision of the peritoneal mass is feasible.



PATIENT

Mangi Tortop

SPECIES

Canine

BREED

Cotton de tulea

SEX

Male Neutered

AGE

14Y

WEIGHT

6kgs

INTERPRETED BY

Sebastian Schaub, DVM
Dr. med. vet. DipECVDI

**IMAGING
PERFORMED BY**

Mobile Pet Imaging

HOSPITAL NAME

Mobile Pet Imaging

REFERRING VET

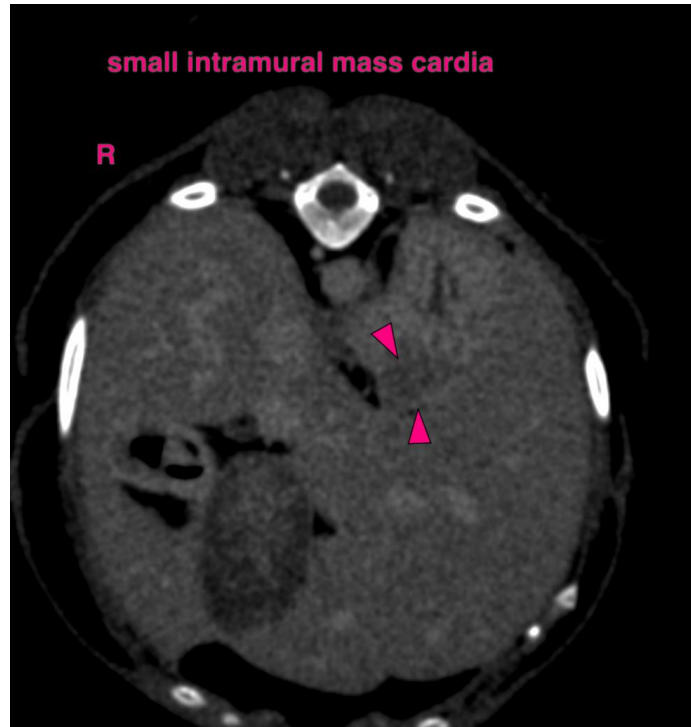
Armstrong

INVOICE

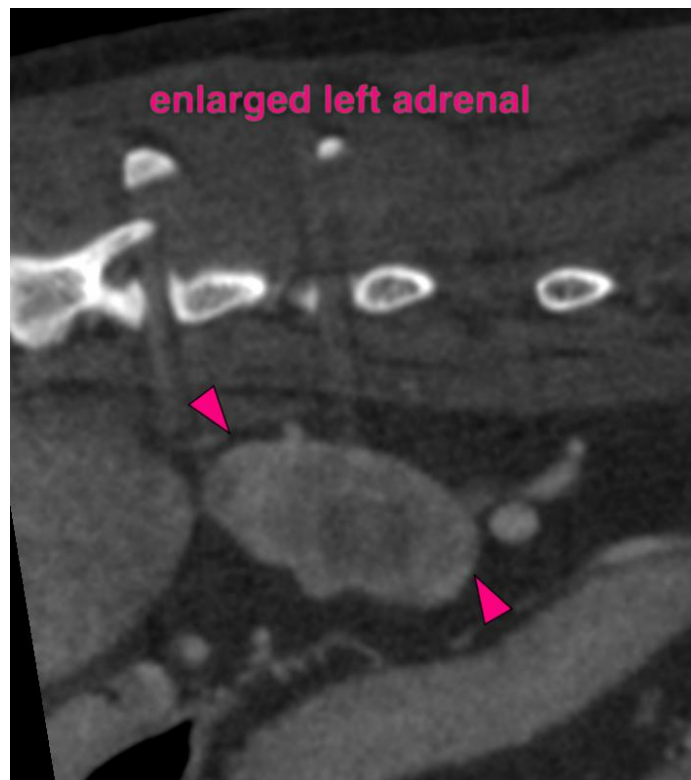
73464

DATE

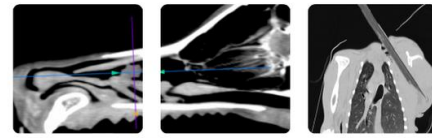
1-26-26



small intramural mass cardia



enlarged left adrenal



PATIENT

Mangi Tortop

SPECIES

Canine

BREED

Cotton de tulea

SEX

Male Neutered

AGE

14Y

WEIGHT

6kgs

INTERPRETED BY

Sebastian Schaub, DVM
Dr. med. vet. DipECVDI

**IMAGING
PERFORMED BY**

Mobile Pet Imaging

HOSPITAL NAME

Mobile Pet Imaging

REFERRING VET

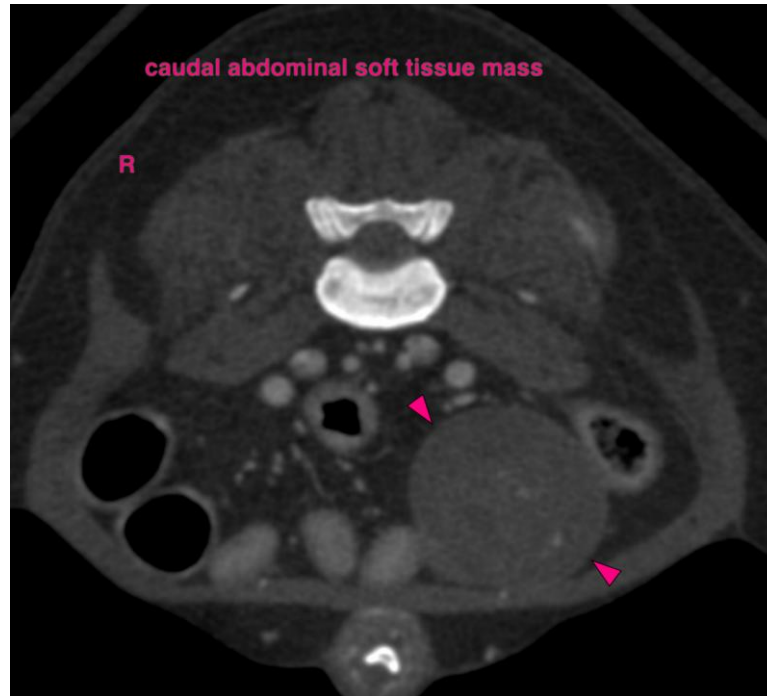Armstrong

INVOICE

73464

DATE

1-26-26



The information and recommendations provided are based on the images presented by the referring veterinarian/sonographer. No evaluation can be communicated regarding pathology that was not visible in the image/video clips provided.

Thank you for this referral. If the clinical or image interpretation does not parallel your findings or if I can be of any further assistance please contact me.

Sebastian Schaub, Sebastian Schaub, DVM, Dr. med. vet. DipECVDI
info@sonopath.com