



PATIENT

Boo Campbell

SPECIES

Rabbit

BREED

Dutch

SEX

Fs

AGE

4Y

WEIGHT

1.8kg

INTERPRETED BY

Sebastian Schaub, DVM
Dr. med. vet. DipECVDI

IMAGING PERFORMED BY

Mobile Pet Imaging

HOSPITAL NAME

Mobile Pet Imaging

REFERRING VET

Armstrong

INVOICE

73470

DATE

1-26-26

PRESENTING CLINICAL SIGNS

Painful, concerns for abnormal parenchyma of liver and kidneys - possibly enlarged

COMPUTED TOMOGRAPHY OF THE ABDOMEN

A high resolution pre- and post-contrast CT study of the abdomen is provided for review.

COMPUTED TOMOGRAPHIC FINDINGS

The serosal fat presents normal attenuation behavior. There is no evidence of peritoneal effusion or peritonitis. A small zone of soft tissue striation is seen level with the absent ovary.

Both kidneys present within normal limits for size, shape and organ architecture. After contrast administration, a bilaterally symmetric and uniform nephro- and pyelogram is noted. The bladder contains a small amount of gravity dependent hyperattenuating urine/sediment - considered physiological

The adrenal glands are within normal limits for size, shape and organ architecture.

Both liver and spleen present with normal shape, even surface, uniformly attenuating parenchyma and homogeneous contrast enhancement, unremarkable.

The pancreas is evenly contoured; the pancreatic parenchyma is homogeneous and presents uniform contrast enhancement.

The position, delineation, wall and content of the gastrointestinal tract are considered within normal limits throughout.

L7 is asymmetric and articulating with the right iliosacral joint and presenting a physiological left transverse process.

COMPUTED TOMOGRAPHIC DIAGNOSIS

- Normal abdomen, but small zone of fat necrosis right caudal abdomen
- Asymmetric lumbosacral transitional vertebra

INTERPRETATION OF THE FINDINGS & FURTHER RECOMMENDATIONS

The CT study of the abdomen reveals no abnormalities; I consider the abdominal organs to be unremarkable.



PATIENT

Boo Campbell

SPECIES

Rabbit

BREED

Dutch

SEX

Fs

AGE

4Y

WEIGHT

1.8kg

INTERPRETED BY

Sebastian Schaub, DVM
Dr. med. vet. DipECVDI

**IMAGING
PERFORMED BY**

Mobile Pet Imaging

HOSPITAL NAME

Mobile Pet Imaging

REFERRING VET

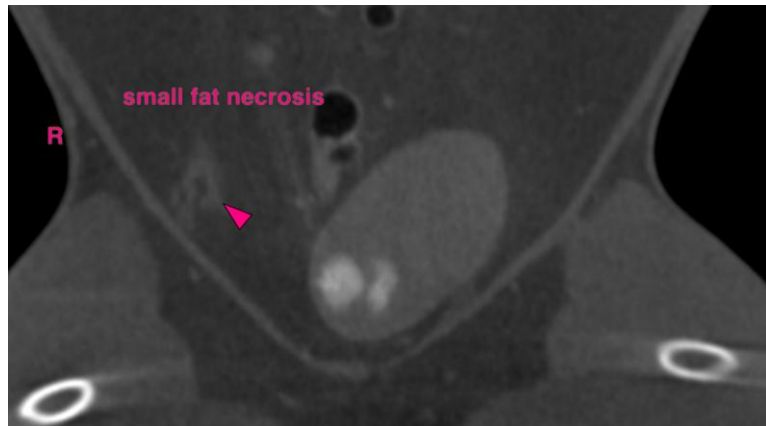
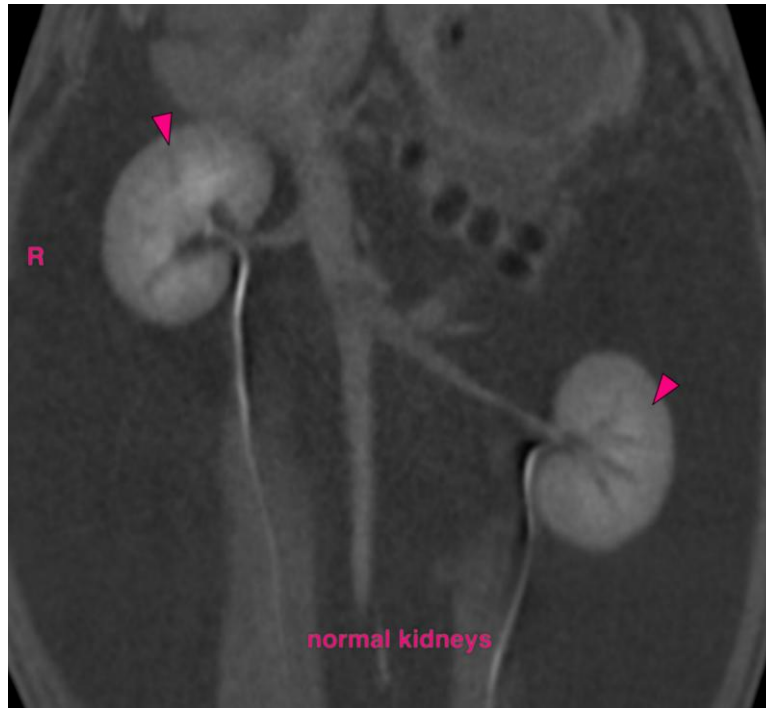
Armstrong

INVOICE

73470

DATE

1-26-26





PATIENT

Boo Campbell

SPECIES

Rabbit

BREED

Dutch

SEX

Fs

AGE

4Y

WEIGHT

1.8kg

INTERPRETED BY

Sebastian Schaub, DVM
Dr. med. vet. DipECVDI

IMAGING PERFORMED BY

Mobile Pet Imaging

HOSPITAL NAME

Mobile Pet Imaging

REFERRING VET

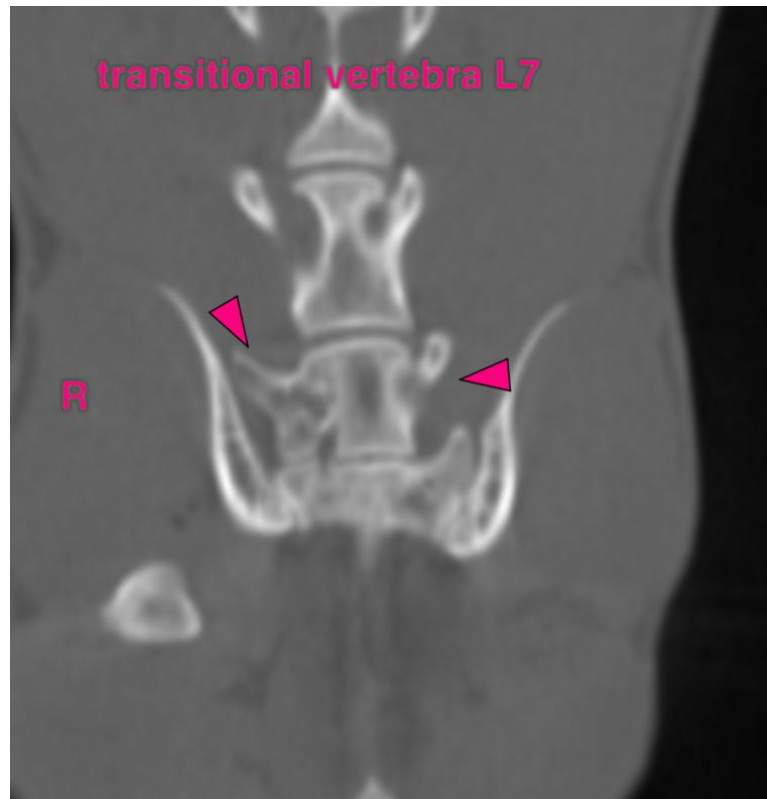
Armstrong

INVOICE

73470

DATE

1-26-26



The information and recommendations provided are based on the images presented by the referring veterinarian/sonographer. No evaluation can be communicated regarding pathology that was not visible in the image/video clips provided.

Thank you for this referral. If the clinical or image interpretation does not parallel your findings or if I can be of any further assistance please contact me.

Sebastian Schaub, Sebastian Schaub, DVM, Dr. med. vet. DipECVDI
info@sonopath.com