



PATIENT

Birdie Krings

SPECIES

Canine

BREED

Cocker Spaniel

SEX

FS

AGE

5 Years

INTERPRETED BY

Sebastian Schaub, DVM
Dr. med. vet. DipECVDI

HOSPITAL NAME

Gentle Doctor Animal
Hospital

REFERRING VET

Dr. Thomassen

INVOICE

56391

DATE

1-26-23

PRESENTING CLINICAL SIGNS

Behavior changes over the past few weeks - not as excitable, holding tail down, prefers to sit. Still E/D well, no V/D.

Abnormal PE/Chem/CBC/UA Results: Resists turning neck to the left side, no obvious discomfort with T-L spine palpation. Mild ataxia (CP deficits) in both hind legs, slightly worse on the right. Chem, CBC, T4, Baseline cortisol completed - no dramatic changes.

RADIOGRAPHIC STUDY OF THE THORACIC & LUMBAR SPINE

Radiographs of the lumbar spine in two orthogonal imaging planes are provided for review.

RADIOGRAPHIC FINDINGS

The body condition score is 8/9.

Mineralized disc material is superimposed on the neuroforamen L2/L3. In the subcutaneous tissue dorsal to L2/L3, small gas inclusions are visible - suspect preceding subcutaneous injection.

The remainder of the osseous and surrounding soft tissue structures of the thoracic & lumbar spine are within normal limits.

RADIOGRAPHIC DIAGNOSIS

- Suspect chondroid disc degeneration L2/L3
- Normal thoracic spine

INTERPRETATION OF THE FINDINGS & FURTHER RECOMMENDATIONS

An underlying cause for the described clinical signs cannot be specified. If there is strong clinical suspicion for underlying myelopathy, cross-sectional imaging can be used as advanced imaging modality.



PATIENT

Birdie Krings

SPECIES

Canine

BREED

Cocker Spaniel

SEX

FS

AGE

5 Years

INTERPRETED BY

Sebastian Schaub, DVM
Dr. med. vet. DipECVDI

HOSPITAL NAME

Gentle Doctor Animal
Hospital

REFERRING VET

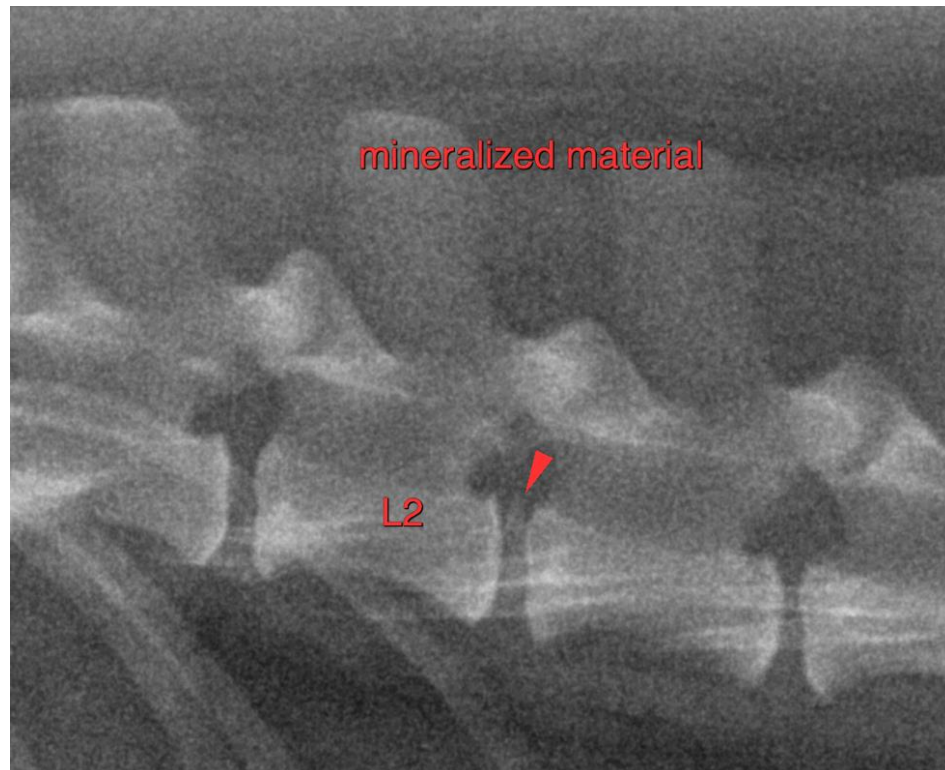
Dr. Thomassen

INVOICE

56391

DATE

1-26-23



The information and recommendations provided are based on the images presented by the referring veterinarian/sonographer. No evaluation can be communicated regarding pathology that was not visible in the image/video clips provided.

Thank you for this referral. If the clinical or image interpretation does not parallel your findings or if I can be of any further assistance please contact me.

Sebastian Schaub, Sebastian Schaub, DVM, Dr. med. vet. DipECVDI
sebast.schaub@gmail.com