



PATIENT

Trinity Sanchez

PRESENTING CLINICAL SIGNS

severe nasal congestion, periodontal Dz

SPECIES

Canine

COMPUTED TOMOGRAPHY OF THE SKULL

A high resolution pre- and post-contrast CT study of the skull is provided for review.

BREED

Miniature Schnauzer

COMPUTED TOMOGRAPHIC FINDINGS

The tooth elements 101-103, 106, 109, 110, 201-203, 206, 210, 301, 305, 306, 310, 311, 401, 405, 406, 410 and 411 are absent. The distal root of triadan 409 presents a marked widening of the periodontal space with local perforation of the ventrolateral aspect of the cortex. Generalized evidence of moderate periodontal disease is noted.

SEX

Female Spayed

The right nasal cavity is obliterated by soft tissue attenuating and heterogeneous contrast enhancing material. Multifocal aggressive osteolytic lesions of the right maxillary bone, perpendicular plate of the right palatine bone and nasal bone is seen. The mass is protruding into the subcutaneous tissue at the right aspect of the nose. The nasal mass is perforating the nasal septum and is bulging into the left nasal cavity. Advanced destruction of the associated conchal & turbinate structures is seen. Advanced lysis of the osseous lining of the right frontal sinus is noted and the nasal mass is bulging both into the left orbit and subcutaneous tissue level with the right frontal sinus. Destruction of the cribriform plate is present, and the nasal mass is bulging mildly into the rostral fossa cranii.

AGE

12 Years

INTERPRETED BY

Sebastian Schaub, DVM
Dr. med. vet. DipECVDI

Both temporomandibular joints present congruent joint spaces with even subchondral bone surfaces and are considered within normal limits.

Both tympanic bullae are aerated, the mucosal lining is not seen, the bony wall is smooth and thin. The external ear canals are within normal limits.

HOSPITAL NAME

Mobile Pet Imaging

The submandibular lymph nodes bilaterally are prominent.

COMPUTED TOMOGRAPHIC DIAGNOSIS

REFERRING VET

Meaux

- Right sided biologically aggressive nasal soft tissue neoplasia
- Secondary polyostotic aggressive osteolytic lesions and perforation of the cranial fossa
- Lymphadenopathy mandibular lymph nodes
- Periodontal abscess formation 409
- Generalized periodontal disease
- Multiple absent teeth

INVOICE

49868

INTERPRETATION OF THE FINDINGS & FURTHER RECOMMENDATIONS

DATE

1-26-22

The findings are consistent with a biologically aggressive nasal neoplasm, originating from the right nasal cavity with perforation of the cranial fossa and into the right orbit. Differentials include adenocarcinoma, squamous cell carcinoma, transitional cell carcinoma, lymphosarcoma, other. Rhinoscopy including FNA sampling can be used as advanced diagnostic tests. Based on the results of the advanced diagnostic tests, the chances of radiation therapy can be discussed with oncologist. The Adam tumor stage is T4.



PATIENT

Trinity Sanchez

Recommend FNA sampling of the mandibular lymph nodes to rule in/out metastatic spread.
Consider complementing full tumor staging by 3-view thoracic radiographs.

SPECIES

Canine

BREED

Miniature Schnauzer

SEX

Female Spayed

AGE

12 Years

INTERPRETED BY

Sebastian Schaub, DVM
Dr. med. vet. DipECVDI

HOSPITAL NAME

Mobile Pet Imaging

REFERRING VET

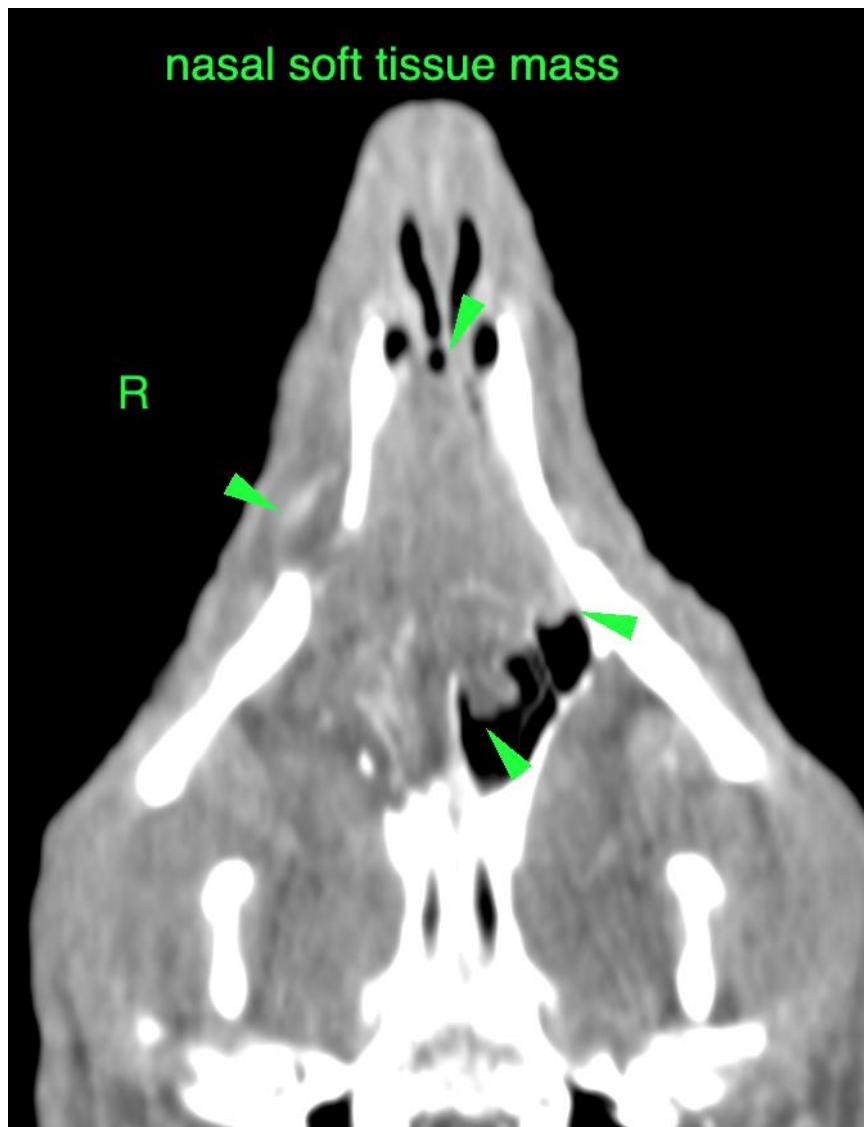Meaux

INVOICE

49868

DATE

1-26-22





PATIENT

Trinity Sanchez

SPECIES

Canine

BREED

Miniature Schnauzer

SEX

Female Spayed

AGE

12 Years

INTERPRETED BY

Sebastian Schaub, DVM
Dr. med. vet. DipECVDI

HOSPITAL NAME

Mobile Pet Imaging

REFERRING VET

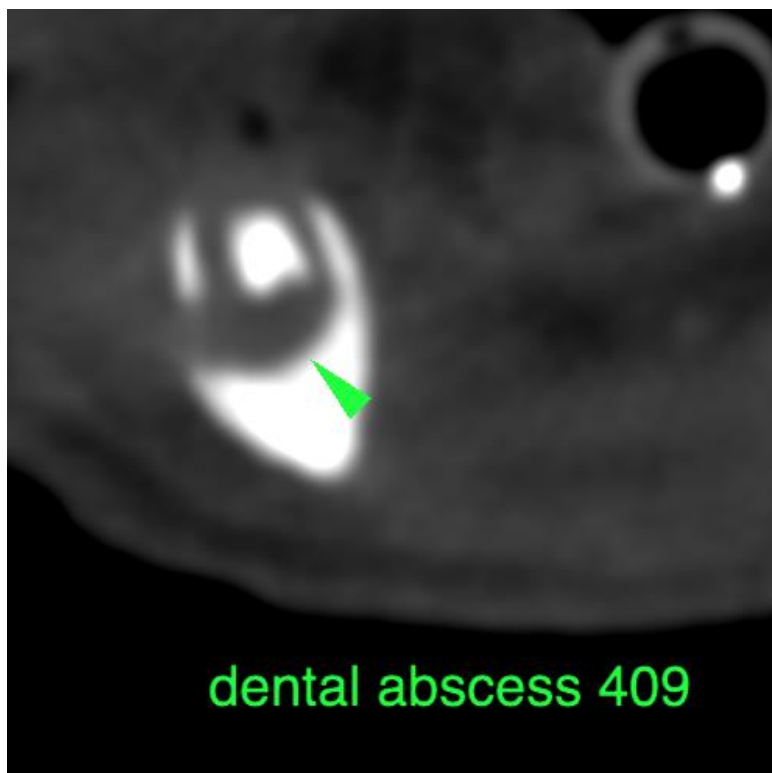
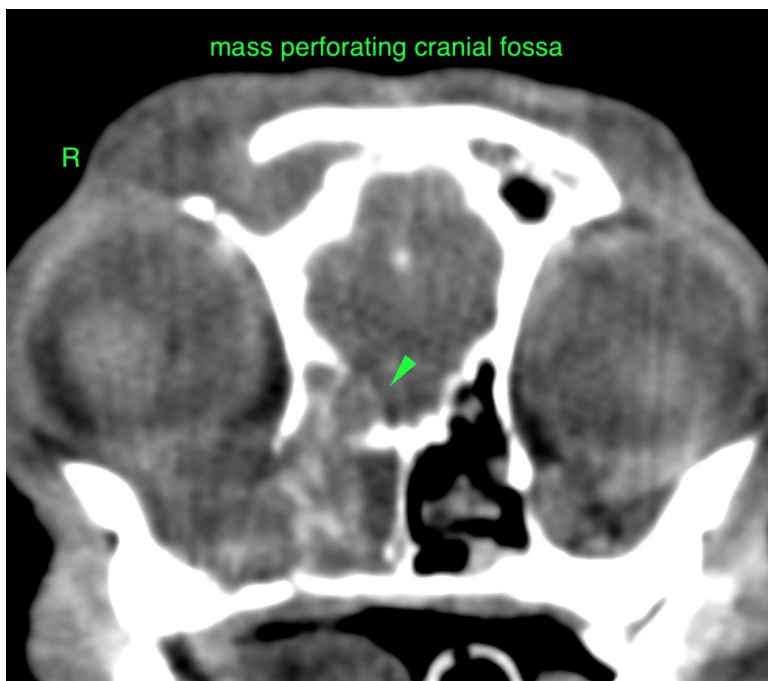
Meaux

INVOICE

49868

DATE

1-26-22





PATIENT

Trinity Sanchez

SPECIES

Canine

BREED

Miniature Schnauzer

SEX

Female Spayed

AGE

12 Years

INTERPRETED BY

Sebastian Schaub, DVM
Dr. med. vet. DipECVDI

HOSPITAL NAME

Mobile Pet Imaging

REFERRING VET

Meaux

INVOICE

49868

DATE

1-26-22

The information and recommendations provided are based on the images presented by the referring veterinarian/sonographer. No evaluation can be communicated regarding pathology that was not visible in the image/video clips provided.

Thank you for this referral. If the clinical or image interpretation does not parallel your findings or if I can be of any further assistance please contact me.

Sebastian Schaub, Sebastian Schaub, DVM, Dr. med. vet. DipECVDI
sebast.schaub@gmail.com