



PATIENT

Mikey Kraus

PRESENTING CLINICAL SIGNS

Always licking his lips a lot. Seemed like his lips were swollen last night. Ate his food great last night and was drinking a lot of water as well. Didn't really want to eat his food this morning but finally eat it. Also has been having a hard time swallowing his food last night.

SPECIES

Canine

Abnormal PE/Chem/CBC/UA Results: PE: Everything looked great CBC: RDW 14.4% Neutrophils 12.92 K/uL Eosinophils 0.08k/uL Chem: Chloride 105mmol/L ALT 384 U/L ALP 340 U/L GGT 55U/L Bilirubin - Total 1.1 mg/dL

BREED

Golden Retriever

RADIOGRAPHIC STUDY OF THE ABDOMEN

Radiographs of the abdomen in three imaging planes are provided for review.

SEX

Neutered

RADIOGRAPHIC FINDINGS

The surrounding bony structures are within normal limits.

No abnormalities of the extraabdominal soft tissues are noted. The abdominal wall is smooth and thin.

AGE

7 Years, 10 Months

The serosal detail is maintained throughout the peritoneal and retroperitoneal space.

The liver is appropriate in position, size and presents uniform opacity.

The splenic head is in the anticipated position and within normal limits for size and opacity.

INTERPRETED BY

Sebastian Schaub, DVM
Dr. med. vet. DipECVDI

Both kidneys are seen and present with normal size, shape, delineation and opacity. The urinary bladder is in its anticipated position. No radiopaque calculi are noted throughout the upper and lower urinary tract.

HOSPITAL NAME

Elizabeth Animal Hospital

The stomach is moderately to distended, containing unstructured gas & soft tissue opaque material as well as an innumerable amount of roundish soft tissue opaque bodies, demarcated by a gas opaque rim. In the region of the pyloric antrum, granular mineralized material is visible - 'gravel sign'.

The small intestinal loops are of even diameter and non-dilated, a small amount of gas is seen within the small intestinal loops and considered within normal limits.

REFERRING VET

Kim Allyn, DVM

The colon is seen in the expected position and presents with appropriate content.

RADIOGRAPHIC DIAGNOSIS

INVOICE

49867

- Potential gastric emptying disorder
- Moderately distended stomach by heterogeneous material

INTERPRETATION OF THE FINDINGS & FURTHER RECOMMENDATIONS

DATE

1-26-22

Given the history of recent food intake, the material in the stomach is considered to be consistent with 'normal' ingesta such as kibbles. However, the dilation and gravel sign are concerning for gastric emptying disorder and gastric foreign material is a consideration here. Depending on the clinical development - persistent nausea? - I would recommend follow up radiographs after the fasting the patient for at least 12h.



PATIENT

If not done so yet, complementing workup by cpl appears beneficial as well.

Mikey Kraus

SPECIES

Canine

BREED

Golden Retriever

SEX

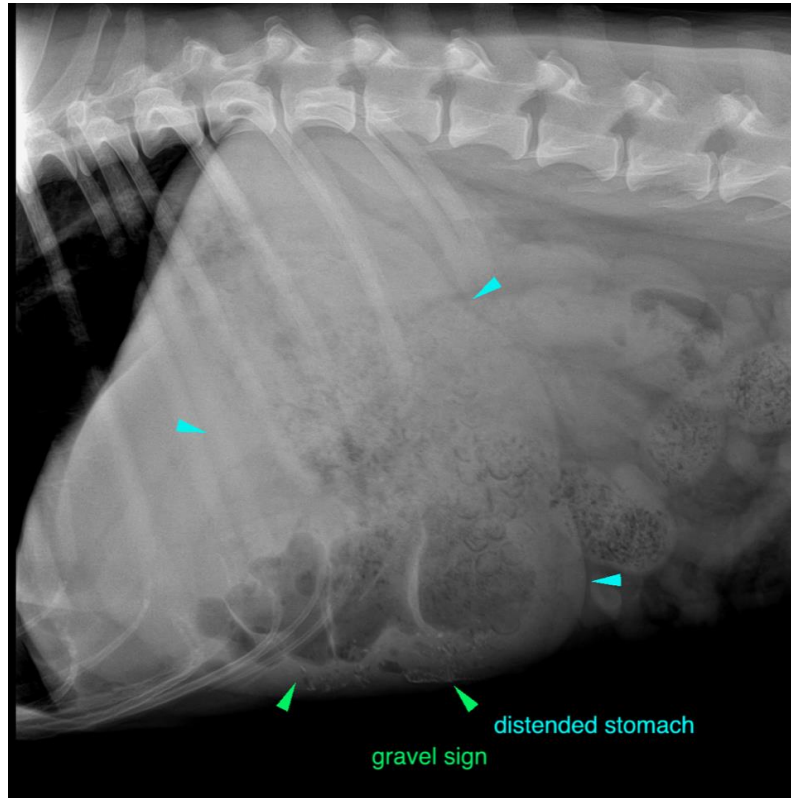
Neutered

AGE

7 Years, 10 Months

INTERPRETED BY

Sebastian Schaub, DVM
Dr. med. vet. DipECVDI



HOSPITAL NAME

Elizabeth Animal
Hospital

The information and recommendations provided are based on the images presented by the referring veterinarian/sonographer. No evaluation can be communicated regarding pathology that was not visible in the image/video clips provided.

REFERRING VET

Kim Allyn, DVM

Thank you for this referral. If the clinical or image interpretation does not parallel your findings or if I can be of any further assistance please contact me.

Sebastian Schaub, Sebastian Schaub, DVM, Dr. med. vet. DipECVDI
sebast.schaub@gmail.com

INVOICE

49867

DATE

1-26-22