



**PATIENT**

Lola Singh

**PRESENTING CLINICAL SIGNS**

Limping. inspection on walk- LH lame 2/5, BAR, m.m-pink, CRT<2sec, EENT, H/L, Abdo, U/G, skin and coat, M/S- patellar luxation bilaterally, crepitation on L stifle A: patellar luxation

**SPECIES**

CAnine

**RADIOGRAPHIC STUDY OF THE PELVIS AND STIFLE JOINTS**

A complete set of radiographs of the pelvis and stifle joints is provided for review.

**BREED**

French Bulldog

**RADIOGRAPHIC FINDINGS**

The osseous and surrounding soft tissue structures of the pelvis are within normal limits. The coxofemoral joints present with a congruent joint space, unremarkable.

In the craniocaudal projection, the patella of the left stifle joint is in a relative medial position.

**SEX**

Spayed

The left stifle joint presents smooth osseous margins, without signs of intracapsular swelling.

The stifle joint without side marker is considered as the right stifle joint and presents a moderate intracapsular soft tissue swelling displacing the infrapatellar fat pad. The osseous margins of the right stifle joint are smooth.

**AGE**

1 Year

**RADIOGRAPHIC DIAGNOSIS**

- Articular swelling right stifle joint
- Suspect left sided patellar luxation

**INTERPRETED BY**

Sebastian Schaub, DVM  
Dr. med. vet. DipECVDI

**INTERPRETATION OF THE FINDINGS & FURTHER RECOMMENDATIONS**

At this point the radiographic study presents no specific pathology, explaining the acute onset of clinical signs. Contusion or distortion might be a potential. If patellar luxation is the cause for hind limb lameness, I would expect a more chronic history. Consider a clinical trial with NSAID and rest and reevaluation the patient in 2-3 weeks.

**HOSPITAL NAME**

Animal Paradise  
Hospital

**REFERRING VET**

Dr. Mostafa Elshafie

**INVOICE**

49881

**DATE**

1-26-22



**PATIENT**

Lola Singh

**SPECIES**

CAnine

**BREED**

French Bulldog

**SEX**

Spayed

**AGE**

1 Year

**INTERPRETED BY**

Sebastian Schaub, DVM  
Dr. med. vet. DipECVDI

**HOSPITAL NAME**

Animal Paradise  
Hospital

**REFERRING VET**

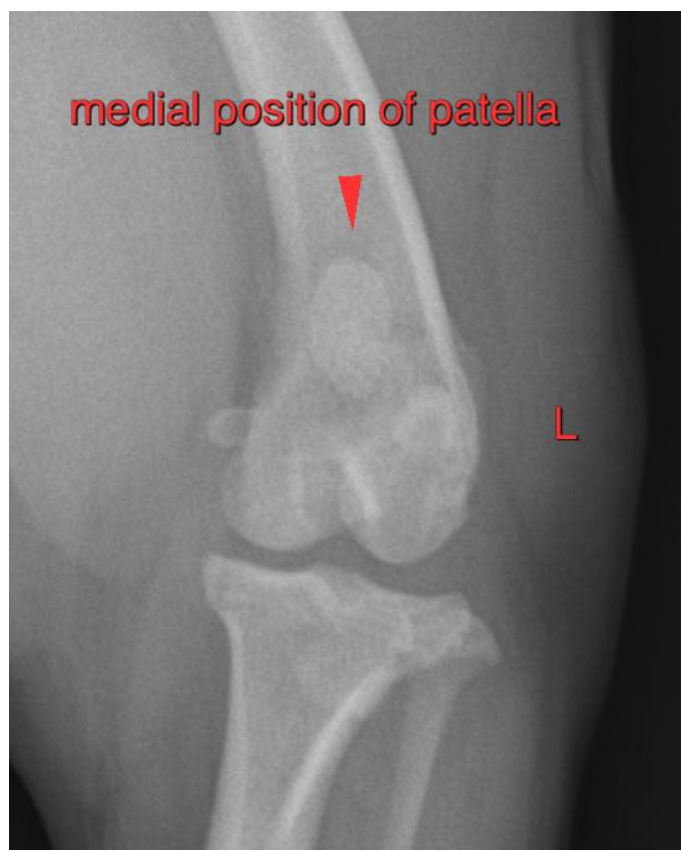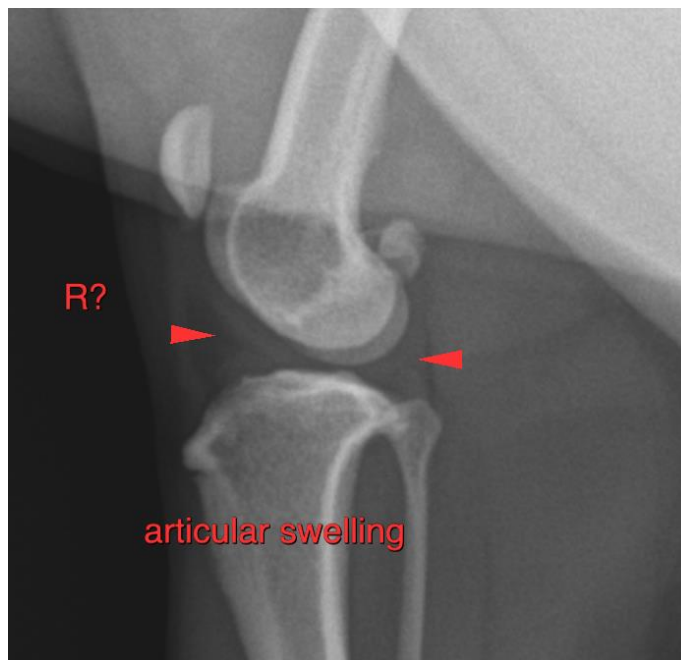
Dr. Mostafa Elshafie

**INVOICE**

49881

**DATE**

1-26-22





**PATIENT**

Lola Singh

The information and recommendations provided are based on the images presented by the referring veterinarian/sonographer. No evaluation can be communicated regarding pathology that was not visible in the image/video clips provided.

**SPECIES**

CAnine

Thank you for this referral. If the clinical or image interpretation does not parallel your findings or if I can be of any further assistance please contact me.

**BREED**

French Bulldog

**Sebastian Schaub**, Sebastian Schaub, DVM, Dr. med. vet. DipECVDI  
sebast.schaub@gmail.com

**SEX**

Spayed

**AGE**

1 Year

**INTERPRETED BY**

Sebastian Schaub, DVM  
Dr. med. vet. DipECVDI

**HOSPITAL NAME**

Animal Paradise  
Hospital

**REFERRING VET**

Dr. Mostafa Elshafie

**INVOICE**

49881

**DATE**

1-26-22