



PATIENT

Meg Stone

PRESENTING CLINICAL SIGNS

lame on left hind x 2 weeks, improved tremendously on carprofen under sedation she has no drawer sign Mildly thickened left anal gland
Abnormal PE/Chem/CBC/UA Results: mild neutropenia

SPECIES

Canine

RADIOGRAPHIC STUDY OF THE THORAX, LUMBAR SPINE AND STIFLE JOINTS

A complete set of radiographs of the thorax, the lumbar spine and the stifle joints

BREED

Border Collie mmix

RADIOGRAPHIC FINDINGS

Thorax

The surrounding bony structures are within normal limits.

The extrathoracic soft tissues present homogeneous without abnormalities.

SEX

FS

The heart is of normal size and shape, there is no evidence of cardiac chamber or vascular enlargement. The pulmonary vasculature is within normal limits.

AGE

9 Years

The cranial mediastinum presents the expected soft tissue opacity. The mediastinal width is less than twice the width of the vertebral column at the same level.

The trachea is normal in diameter and presents the anticipated course. The luminal outline of the trachea is smooth.

INTERPRETED BY

Sebastian Schaub, DVM
Dr. med. vet. DipECVDI

The bronchial tree presents with thin walls and tapers uniformly towards the periphery as expected.

The lung parenchyma presents the expected architecture and opacity; the intrapulmonary vascular branching is seen up to the third order lung vessels.

HOSPITAL NAME

Northshore
Veterinary Hospital

The diaphragm is well delineated with even surface and the expected mild cranial bulging of the diaphragmatic cupola.

Lumbar spine and hind limbs

The vertebral endplates L7/S1 present moderate spondylosis formation. The remainder of the osseous and soft tissue structures of the lumbar spine are within normal limits.

REFERRING VET

Brita Kiffney

The periarticular bones of the left stifle joint present mild osteophyte new bone formation. A moderate intracapsular soft tissue swelling of the left stifle joint is appreciated, distorting the infrapatellar fat pad cranially and the fascial plane caudally. Mild cranial subluxation of the left tibia is appreciated.

INVOICE

56383

The periarticular bones of the right stifle joint present mild osteophyte new bone formation. A mild intracapsular swelling of the left stifle joint is seen.

RADIOGRAPHIC DIAGNOSIS

DATE

1-25-23

- Mild degenerative osteoarthritis stifle joints bilaterally, L>R
- Articular swelling stifle joints bilaterally, L>R
- Mild cranial subluxation left tibia
- Spondylosis deformans lumbosacral junction



PATIENT • Normal thorax

Meg Stone

INTERPRETATION OF THE FINDINGS & FURTHER RECOMMENDATIONS

SPECIES

Canine

The radiographic study is consistent with bilateral mild chronic degenerative osteoarthritis with concomitant joint effusion of both stifle joints. Given the mild subluxation of the left tibia failure of the left cranial cruciate ligament is present. The changes of right stifle joint are suggestive for and early stage of pathology of the cranial cruciate ligament. Accompanying pathology of the menisci might be present.

BREED

A positive drawer sign or tibial compression test under general anesthesia will confirm the diagnosis.

Border Collie mmix

SEX

FS

AGE

9 Years

INTERPRETED BY

Sebastian Schaub, DVM
Dr. med. vet. DipECVDI

HOSPITAL NAME

Northshore
Veterinary Hospital

REFERRING VET

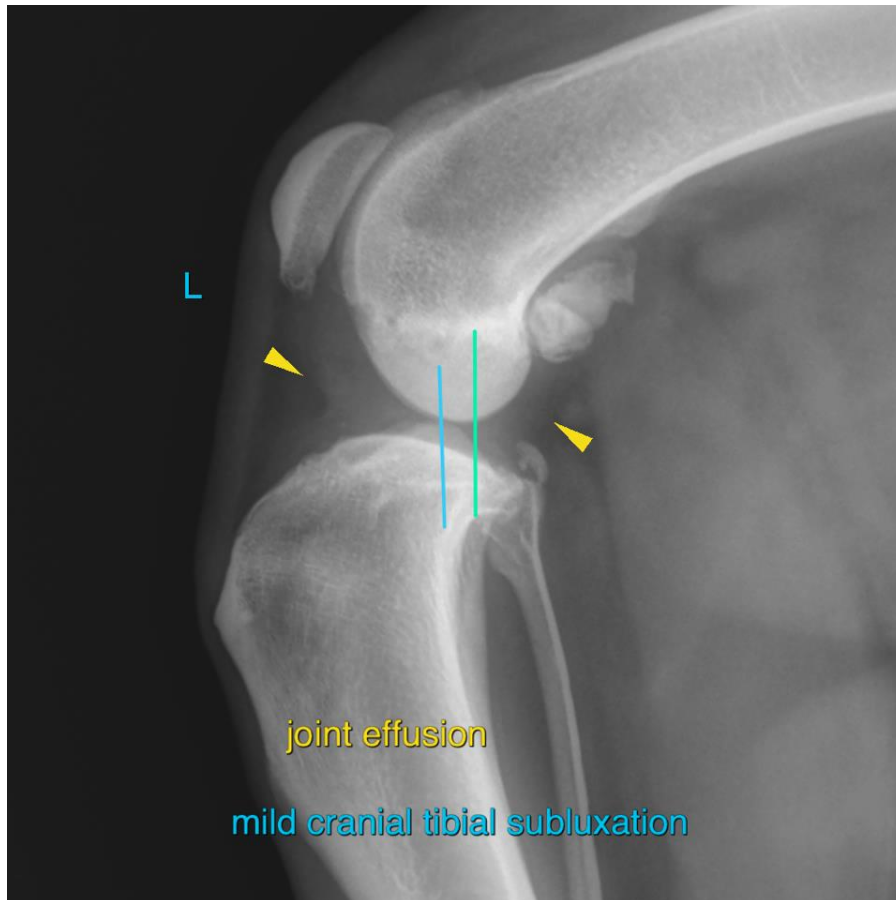
Brita Kiffney

INVOICE

56383

DATE

1-25-23





PATIENT

Meg Stone

SPECIES

Canine

BREED

Border Collie mmix

SEX

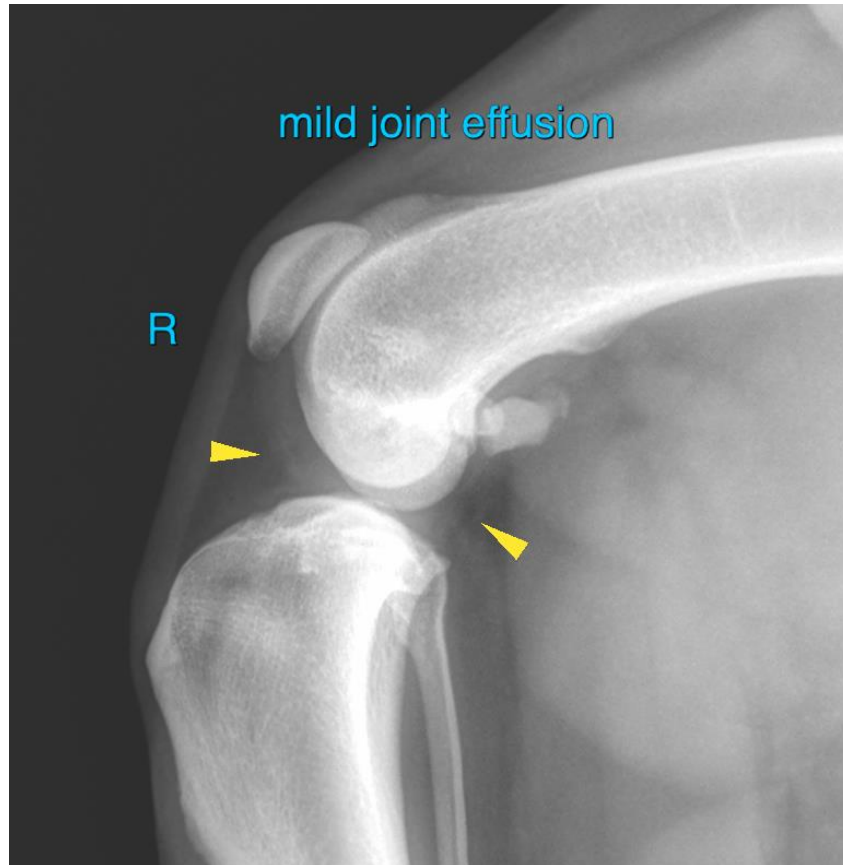
FS

AGE

9 Years

INTERPRETED BY

Sebastian Schaub, DVM
Dr. med. vet. DipECVDI



HOSPITAL NAME

Northshore
Veterinary Hospital

REFERRING VET

Brita Kiffney

INVOICE

56383

DATE

1-25-23

The information and recommendations provided are based on the images presented by the referring veterinarian/sonographer. No evaluation can be communicated regarding pathology that was not visible in the image/video clips provided.

Thank you for this referral. If the clinical or image interpretation does not parallel your findings or if I can be of any further assistance please contact me.

Sebastian Schaub, Sebastian Schaub, DVM, Dr. med. vet. DipECVDI
sebast.schaub@gmail.com