



PATIENT

Rico White

PRESENTING CLINICAL SIGNS

Bilateral shoulder OCD, suspected elbow dysplasia due to atypical stance of right front leg not associated with either diagnosis, poss other congenital problems.
Abnormal PE/Chem/CBC/UA Results: WNL

SPECIES

Canine

COMPUTED TOMOGRAPHY OF THE FRONT LIMBS

A high resolution pre- and post-contrast CT study of the front limbs are provided for review.

BREED

Great Dane

COMPUTED TOMOGRAPHIC FINDINGS

The subchondral bone of the humeral head bilaterally presents an irregular crescent shaped defect, measuring approximately 1.2 x 1.6 cm in size. The defect of the subchondral bone of the humeral head bilaterally is demarcated by moderate sclerosis. Mild osteophyte formation is seen at the caudal aspect of the right shoulder joint.

SEX

MI

The elbow joints bilaterally present smooth osseous margins, unremarkable. The medial coronoid process

AGE

1 Year

In the right proximal diaphysis of the radius & ulna, a zone with mild cloudy sclerosis is seen - region of the nutritional foramen.

INTERPRETED BY

Sebastian Schaub, DVM
Dr. med. vet. DipECVDI

No abnormalities of the osseous and surrounding soft tissue structures of the antebrachium & carpal joints are appreciated.

COMPUTED TOMOGRAPHIC DIAGNOSIS

- Osteochondrosis dissecans (OCD) humeral head bilaterally
- Mild degenerative osteoarthritis right shoulder joint
- Suspect mild right sided panosteitis of the radius
- Normal elbow joints & carpal joints bilaterally

HOSPITAL NAME

Bridgwater
Veterinary Hospital
and Wellness Centre

INTERPRETATION OF THE FINDINGS & FURTHER RECOMMENDATIONS

The panosteitis might be an explanation for the clinically appreciated abnormal stance - check if pain can be elicited by pressure on the diaphysis of the radius/ulna, supporting the diagnosis.

REFERRING VET

Dr. Preston

There is no evidence of coronoid disease or incongruity of the elbow joints.

INVOICE

49840

DATE

1-25-22



PATIENT

Rico White

SPECIES

Canine

BREED

Great Dane

SEX

MI

AGE

1 Year

INTERPRETED BY

Sebastian Schaub, DVM
Dr. med. vet. DipECVDI

HOSPITAL NAME

Bridgwater
Veterinary Hospital
and Wellness Centre

REFERRING VET

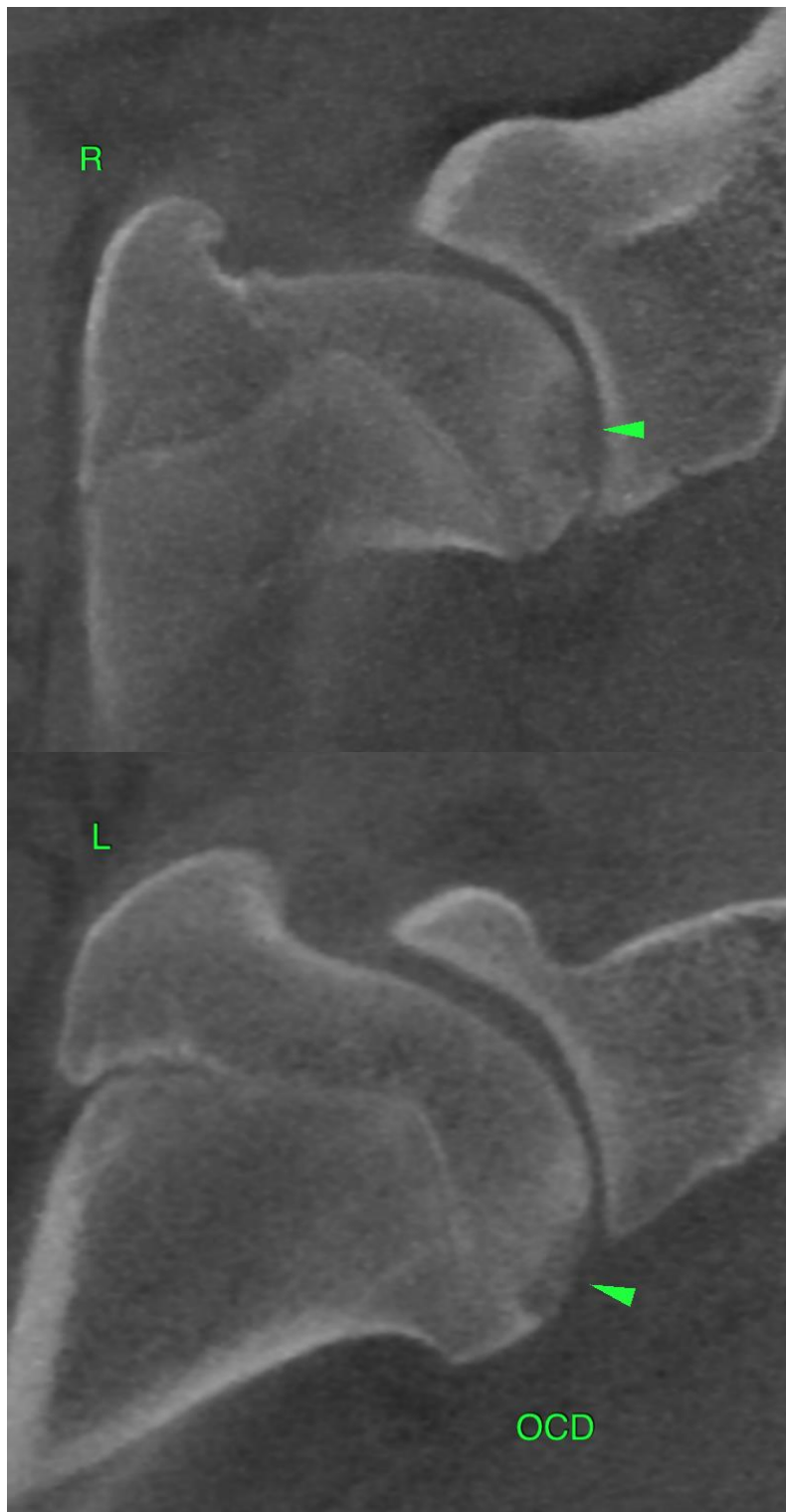
Dr. Preston

INVOICE

49840

DATE

1-25-22





PATIENT

Rico White

SPECIES

Canine

BREED

Great Dane

SEX

MI

AGE

1 Year

INTERPRETED BY

Sebastian Schaub, DVM
Dr. med. vet. DipECVDI

HOSPITAL NAME

Bridgwater
Veterinary Hospital
and Wellness Centre

REFERRING VET

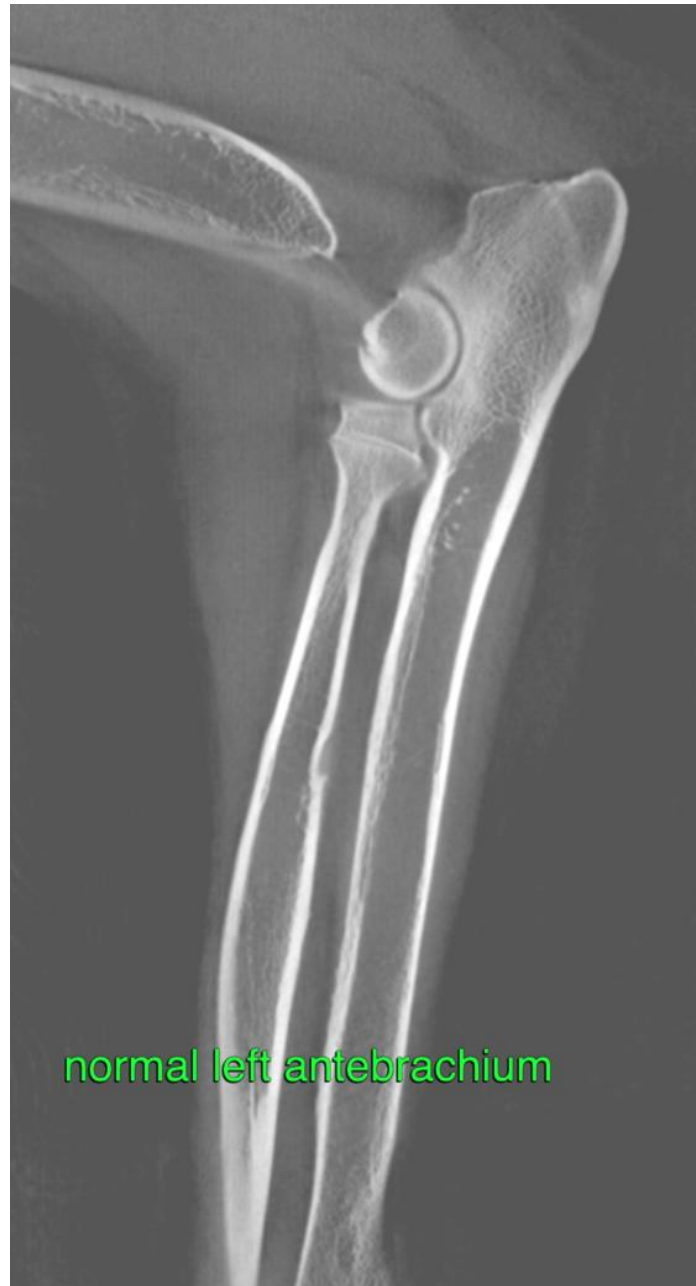Dr. Preston

INVOICE

49840

DATE

1-25-22





PATIENT

Rico White

SPECIES

Canine

BREED

Great Dane

SEX

MI

AGE

1 Year

INTERPRETED BY

Sebastian Schaub, DVM
Dr. med. vet. DipECVDI

HOSPITAL NAME

Bridgwater
Veterinary Hospital
and Wellness Centre

REFERRING VET

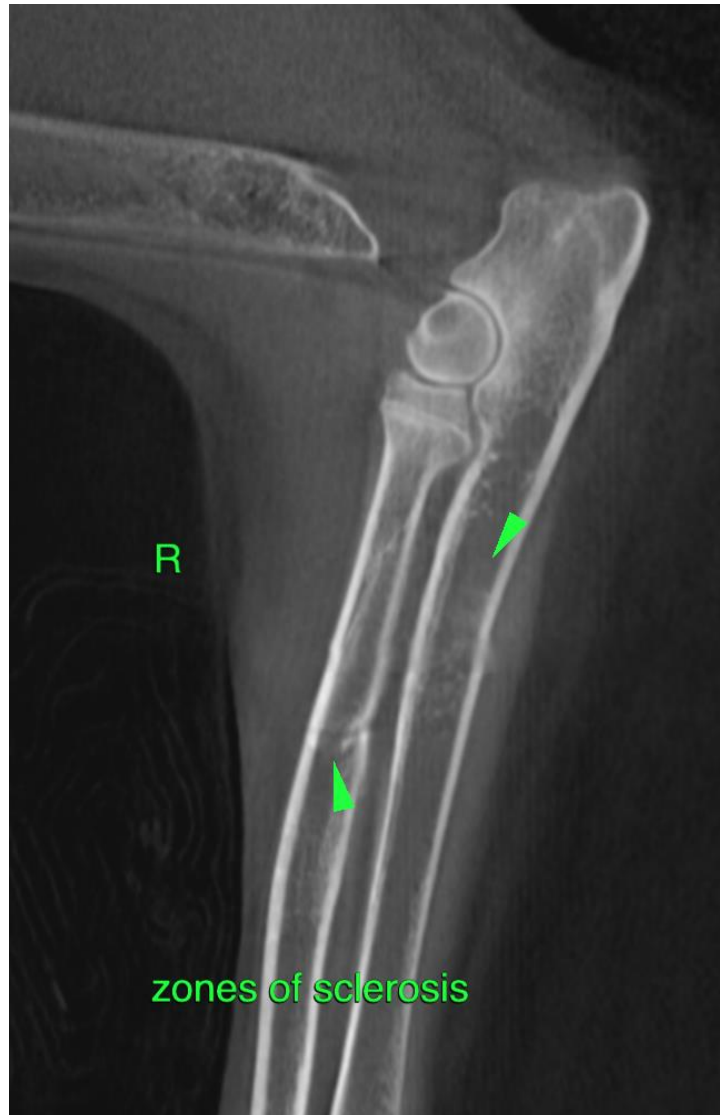Dr. Preston

INVOICE

49840

DATE

1-25-22



The information and recommendations provided are based on the images presented by the referring veterinarian/sonographer. No evaluation can be communicated regarding pathology that was not visible in the image/video clips provided.

Thank you for this referral. If the clinical or image interpretation does not parallel your findings or if I can be of any further assistance please contact me.

Sebastian Schaub, Sebastian Schaub, DVM, Dr. med. vet. DipECVDI
sebast.schaub@gmail.com