



PATIENT PRESENTING CLINICAL SIGNS

Max Delgado
Surgical Planning Mass of soft tissue palate.
Abnormal PE/Chem/CBC/UA Results: CBC --- unremarkable CHEM --- unremarkable

SPECIES COMPUTED TOMOGRAPHY OF THE SKULL

Canine
A high resolution pre- and post-contrast CT study of the skull including the neck is provided for review.

BREED COMPUTED TOMOGRAPHIC FINDINGS

Chihuahua
The tooth elements 106, 107, 206, 306 and 406 are absent. The periodontal space of triadan 104 is moderately widened.

SEX
NM
In both nasal cavities, a mild amount of fluid attenuating material is attached to the nasal mucosal lining. The nasopharynx is obliterated by a significant ill-defined soft tissue swelling. Post contrast administration, the mass presents a heterogeneous contrast enhancement pattern, sparing multiple hypoattenuating regions centrally. The ill-defined swelling is extending laterally up to the left tympanic bulla, caudally up to the caudal aspect of the left tympanic bulla and rostrally up to the level of the caudal margin of the palatine bone. The swelling is measuring approximately 2.0 x 1.7 x 3.8 cm in size. The soft palate is deviated ventrally by the mass effect.

AGE

8 Years
The left tympanic bulla contains a moderate amount of non-contrast enhancing soft tissue material.

INTERPRETED BY

Sebastian Schaub, DVM
Dr. med. vet. DipECVDI
The medial retropharyngeal lymph nodes bilaterally are prominent, uniform soft tissue attenuating and contrast enhancing.

HOSPITAL NAME

Both temporomandibular joints present congruent joint spaces with even subchondral bone surfaces and are considered within normal limits.

Veterinary Image Center

The brain presents no deviation from normal anatomy and symmetry. The brain parenchyma is homogeneous and within normal limits for attenuation and distribution of contrast enhancement. The ventricular system is non-dilated and symmetric.

REFERRING VET

Dr. C. Mongil, DVM

COMPUTED TOMOGRAPHIC DIAGNOSIS

- Soft tissue mass nasopharynx with regions of necrosis or cystic lesions
- Secondary upper airway obstruction and rhinitis
- Lymphadenopathy medial retropharyngeal lymph nodes
- Left sided otitis media – likely due to mechanical obstruction of the auditory tube by the mass
- Bilateral lymphadenopathy medial retropharyngeal lymph nodes
- Periodontal disease 104
- Multiple absent teeth

INVOICE

49793

DATE

1-25-22

INTERPRETATION OF THE FINDINGS & FURTHER RECOMMENDATIONS

The findings are highly concerning for neoplastic disease within the nasopharynx with secondary upper airway obstruction. The exact origin of the mass cannot be defined – soft palate, mucosal lining of nasopharynx, retropharyngeal tissue. Potentials include adenocarcinoma, squamous cell



PATIENT

Max Delgado

carcinoma, melanoma, myxosarcoma, lymphosarcoma, other. Due to the marked soft tissue component and lack of overt inflammatory changes of the surrounding fat, an abscess is considered less likely here. Consider FNA sampling biopsy for further definition. Based on imaging findings complete surgical excision of the mass appears not feasible – chances of (adjuvant) radiation therapy can be discussed with oncologist.

SPECIES

Canine

Recommend FNA sampling of the medial retropharyngeal lymph nodes to rule out metastatic spread

BREED

Chihuahua

SEX

NM

AGE

8 Years

INTERPRETED BY

Sebastian Schaub, DVM
Dr. med. vet. DipECVDI

HOSPITAL NAME

Veterinary Image
Center

REFERRING VET

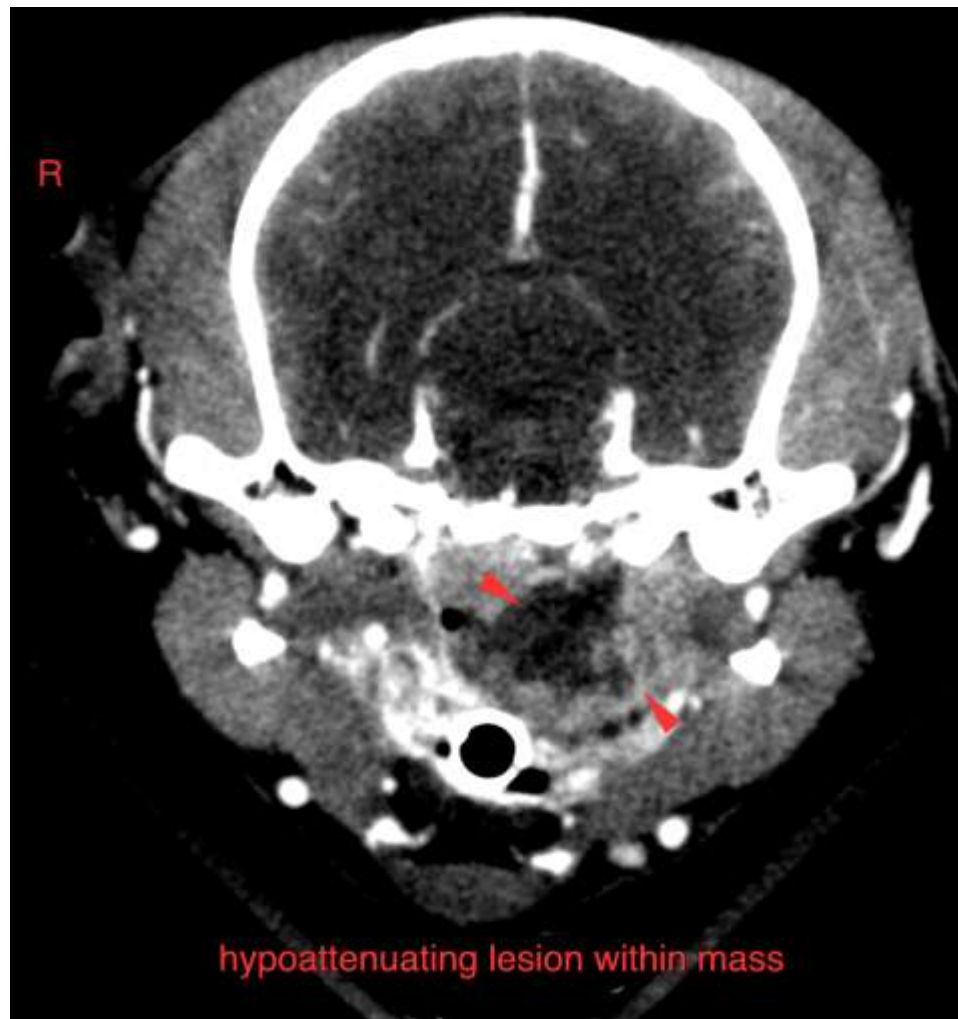
Dr. C. Mongil, DVM

INVOICE

49793

DATE

1-25-22





PATIENT

Max Delgado

SPECIES

Canine

BREED

Chihuahua

SEX

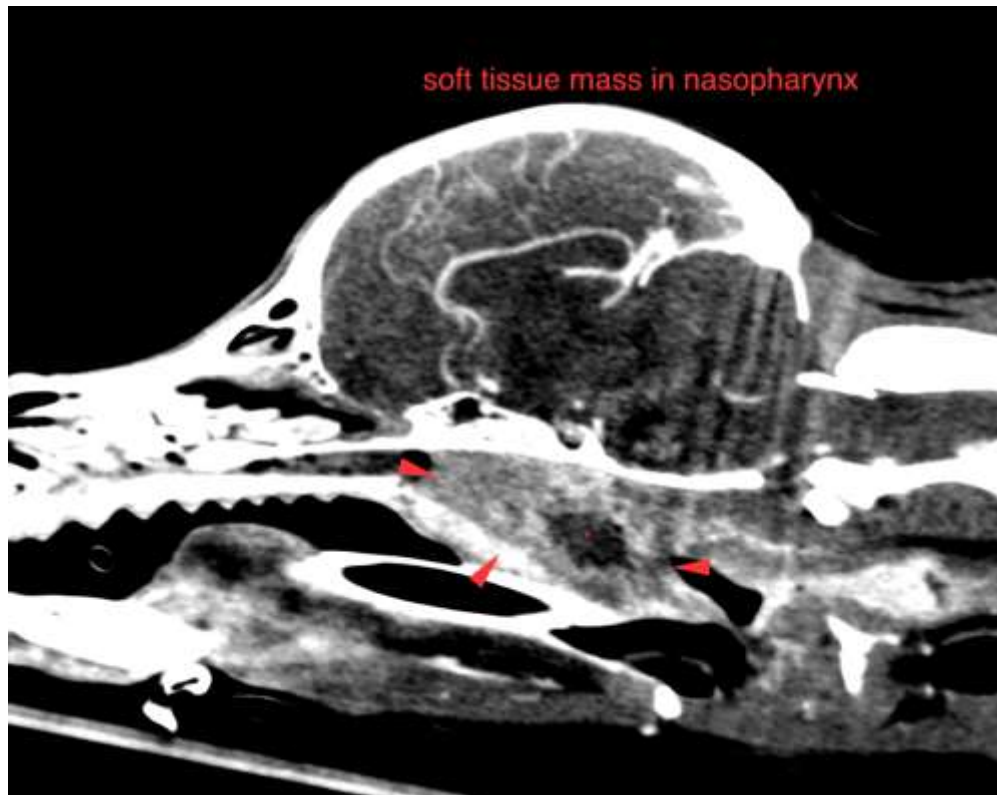NM

AGE

8 Years

INTERPRETED BY

Sebastian Schaub, DVM
Dr. med. vet. DipECVDI



HOSPITAL NAME

Veterinary Image
Center

REFERRING VET

Dr. C. Mongil, DVM

INVOICE

49793

DATE

1-25-22

The information and recommendations provided are based on the images presented by the referring veterinarian/sonographer. No evaluation can be communicated regarding pathology that was not visible in the image/video clips provided.

Thank you for this referral. If the clinical or image interpretation does not parallel your findings or if I can be of any further assistance please contact me.

Sebastian Schaub, Sebastian Schaub, DVM, Dr. med. vet. DipECVDI
sebast.schaub@gmail.com