



PATIENT

Conan James

PRESENTING CLINICAL SIGNS

Conan presented for a mass effect of the right lip, first noticed in September as a small mass and quickly started growing in November. Prior medical history includes laryngeal paralysis which was diagnosed two years ago and idiopathic vestibular disease which resulted in a permanent head tilt to the right.

SPECIES

Canine

COMPUTED TOMOGRAPHY OF THE SKULL & THORAX

A high resolution post-contrast CT study of the skull and thorax is provided for review.

BREED

Mix

COMPUTED TOMOGRAPHIC FINDINGS

Skull

Ankylosis of the roots of the upper & lower incisor, canine and premolar teeth is seen.

SEX

MN

In the region of the right labial commissure, a large, heterogeneous contrast enhancing, irregular spherical mass is visible, measuring 6.8 x 7.2 x 6.7 cm.

AGE

15 Years

The nasal cavity presents the expected aerated spaces between thin & even conchae and turbinates with smooth mucosal lining.

INTERPRETED BY

Sebastian Schaub, DVM
Dr. med. vet. DipECVDI

Both temporomandibular joints present congruent joint spaces with even subchondral bone surfaces and are considered within normal limits.

Both tympanic bullae are aerated, the mucosal lining is not seen, the bony wall is smooth and thin. The external ear canals are within normal limits.

HOSPITAL NAME

Animal Surgical
Center

The brain presents no deviation from normal anatomy and symmetry. The brain parenchyma is homogeneous and within normal limits for attenuation and distribution of contrast enhancement. The ventricular system is non-dilated and symmetric.

The right mandibular lymph nodes are prominent, uniform contrast enhancement pattern; the short-to-long-axis ratio is mildly increased and equals 0.5.

REFERRING VET

Forest Hills Vet Care

A cutaneous wart like lesion is seen dorsal to C2.

Thorax

A lipoma is extending from the right axillary region cranially, along the right lateral aspect of the trachea, up to the level of C4. The trachea is mildly displaced to the right by the mass effect.

INVOICE

49839

The sternal, cranial mediastinal and tracheobronchial lymph nodes are small elongated with a normal short-to-long-axis-ratio is < 0.5, the attenuation and contrast enhancement pattern is uniform and considered within normal limits.

DATE

1-25-22

The cardiovascular structures including the pulmonary vasculature are within normal limits.

The bronchial tree presents with regular branching and tapers uniformly towards the periphery as expected, the bronchial walls are thin and smooth. The bronchus-to-artery ratio is within



PATIENT normal limits.

Conan James The lung parenchyma presents the expected architecture and attenuation behavior with interspersed punctuate mineralization.

SPECIES Small incidental gas pockets are seen within the esophageal lumen, there is no evidence of abnormal dilation.

Canine

COMPUTED TOMOGRAPHIC DIAGNOSIS

- BREED**
- Large soft tissue mass right labial commissure
 - Lymphadenopathy right mandibular lymph node
 - Lipoma right axillary region – extending along the right aspect of the trachea along the neck
 - Cutaneous wart like lesion dorsal aspect of neck
 - Pulmonary osteomas
- Mix

SEX **INTERPRETATION OF THE FINDINGS & FURTHER RECOMMENDATIONS**

MN The findings are fitting the history of soft tissue neoplasm left labial commissure – sarcoma versus carcinoma. FNA sampling/biopsy might be used for further definition. The chances of complete surgical excision of the mass followed by reconstruction of the lib should be discussed with oncologist.

15 Years The prominent mandibular lymph node is equivocal for reactive hyperplasia versus metastatic spread – FNA sampling is recommended for further definition.

INTERPRETED BY

Sebastian Schaub, DVM
Dr. med. vet. DipECVDI

HOSPITAL NAME

Animal Surgical
Center

REFERRING VET

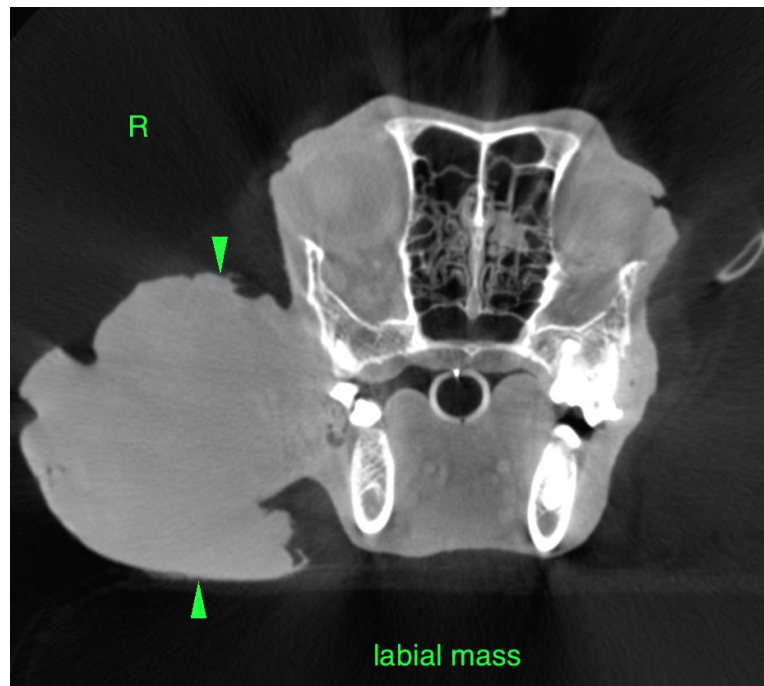
Forest Hills Vet Care

INVOICE

49839

DATE

1-25-22





PATIENT

Conan James

SPECIES

Canine

BREED

Mix

SEX

MN

AGE

15 Years

INTERPRETED BY

Sebastian Schaub, DVM
Dr. med. vet. DipECVDI

HOSPITAL NAME

Animal Surgical
Center

REFERRING VET

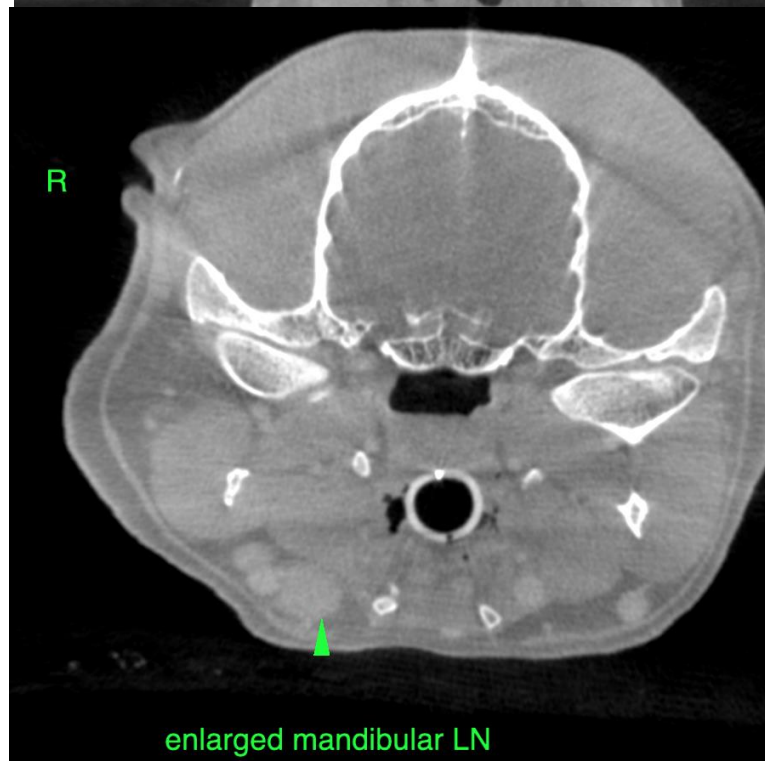
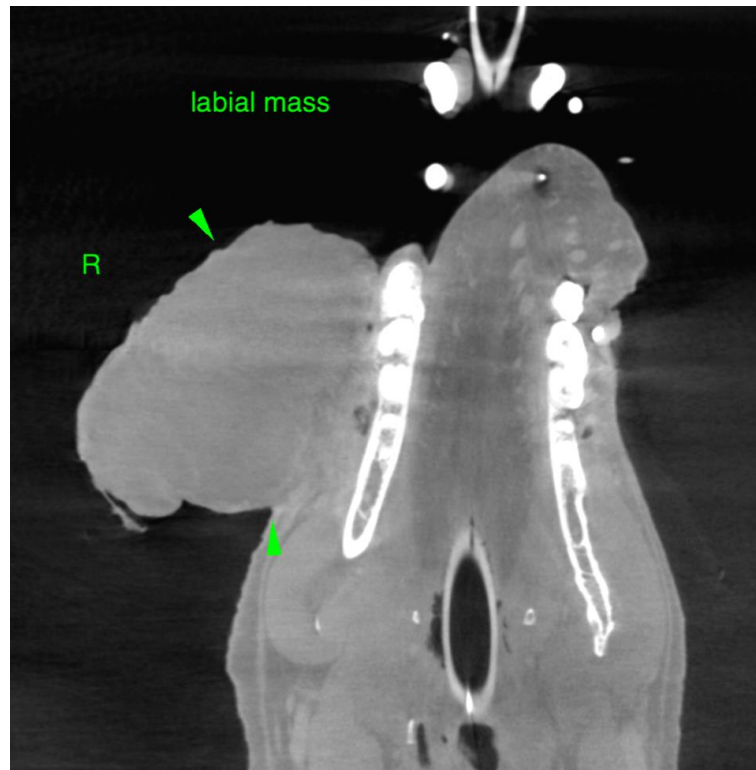
Forest Hills Vet Care

INVOICE

49839

DATE

1-25-22





PATIENT

Conan James

SPECIES

Canine

BREED

Mix

SEX

MN

AGE

15 Years

INTERPRETED BY

Sebastian Schaub, DVM
Dr. med. vet. DipECVDI

HOSPITAL NAME

Animal Surgical
Center

REFERRING VET

Forest Hills Vet Care

INVOICE

49839

DATE

1-25-22

The information and recommendations provided are based on the images presented by the referring veterinarian/sonographer. No evaluation can be communicated regarding pathology that was not visible in the image/video clips provided.

Thank you for this referral. If the clinical or image interpretation does not parallel your findings or if I can be of any further assistance please contact me.

Sebastian Schaub, Sebastian Schaub, DVM, Dr. med. vet. DipECVDI
sebast.schaub@gmail.com