



PATIENT

Athena Hurtado

PRESENTING CLINICAL SIGNS

Pt is limping on RR with mild improvement after a week of nsaids - sedated exam showed mild cranial drawer in both stifles - suspect partial ACLs with bilateral hip dysplasia

SPECIES

Canine

RADIOGRAPHIC STUDY OF THE PELVIS AND STIFLE JOINTS

A complete set of radiographs of the pelvis and the stifle joints is provided for review.

BREED

American Bulldog

RADIOGRAPHIC FINDINGS

The spinous process of S1 is not fused to the spinous process of S2.

Both femoral heads and necks present a shortened femoral neck. The periarticular bones of the coxofemoral joints present mild to moderate osteophyte new bone formation. The acetabular groove bilaterally is shallow, and the center of the femoral heads is lateral to the dorsal acetabular rim.

SEX

SF

The periarticular bones of the stifle joints present moderate osteophyte new bone formation. A moderate intracapsular soft tissue swelling of both stifle joints is seen, displacing the infrapatellar fat pad cranially and distorting the fascial plane caudally.

AGE

2

RADIOGRAPHIC DIAGNOSIS

- Moderate articular swelling stifle joints bilaterally
- Mild degenerative osteoarthritis stifle joints bilaterally
- Mild degenerative osteoarthritis coxofemoral joints bilaterally, due to hip dysplasia

INTERPRETED BY

Sebastian Schaub, DVM
Dr. med. vet. DipECVDI

INTERPRETATION OF THE FINDINGS & FURTHER RECOMMENDATIONS

HOSPITAL NAME

Rockaway Animal Hospital

The radiographic study is consistent with bilateral chronic degenerative osteoarthritis with concomitant joint effusion of both stifle joints. The most-likely underlying cause is (partial) rupture of the cranial cruciate ligament with or without meniscal disease. The diagnosis is supported by the clinically appreciated positive drawer sign / tibial compression test. Surgical treatment management is considered as the therapy of choice.

REFERRING VET

Dr. Ascot

INVOICE

49817

DATE

1-25-22



PATIENT

Athena Hurtado

SPECIES

Canine

BREED

American Bulldog

SEX

SF

AGE

2

INTERPRETED BY

Sebastian Schaub, DVM
Dr. med. vet. DipECVDI

HOSPITAL NAME

Rockaway Animal
Hospital

REFERRING VET

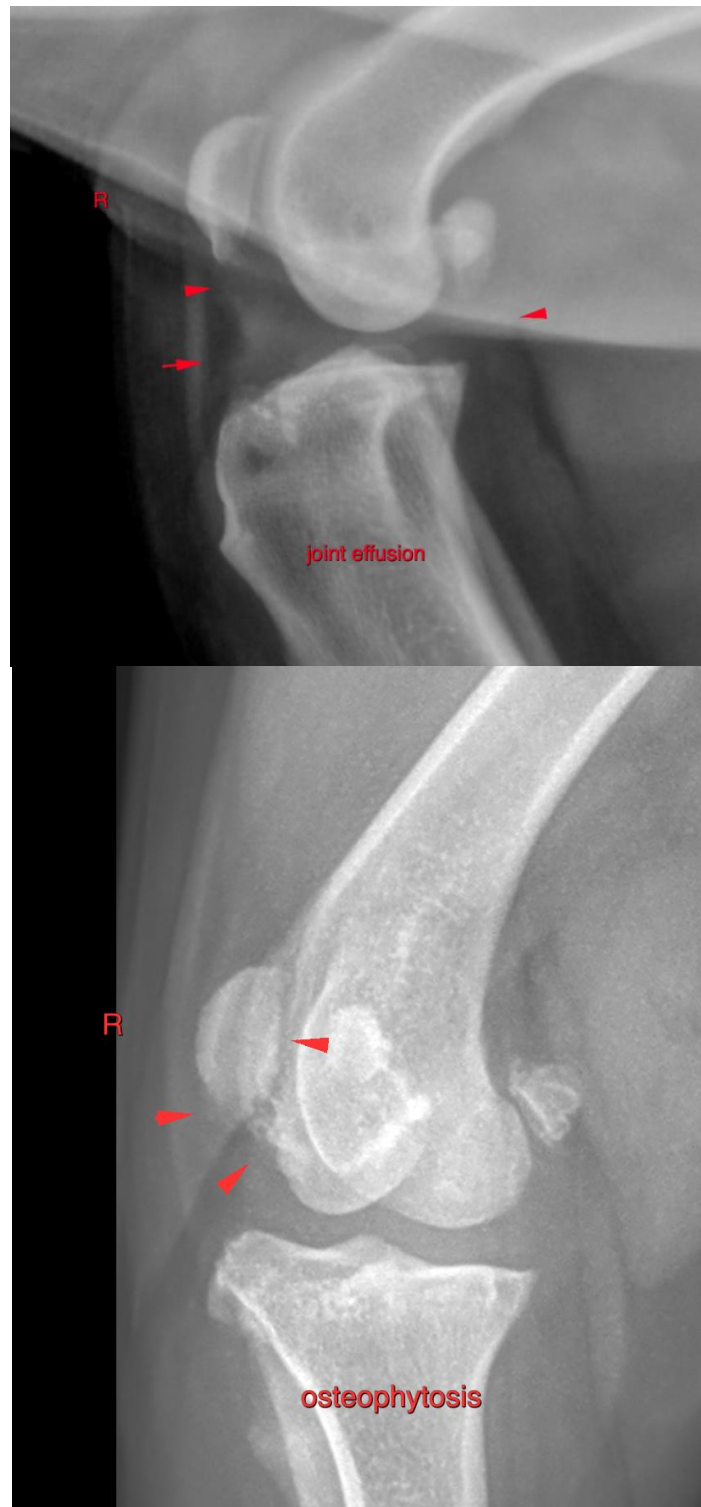Dr. Ascot

INVOICE

49817

DATE

1-25-22





PATIENT

Athena Hurtado

SPECIES

Canine

BREED

American Bulldog

SEX

SF

AGE

2

INTERPRETED BY

Sebastian Schaub, DVM
Dr. med. vet. DipECVDI

HOSPITAL NAME

Rockaway Animal
Hospital

REFERRING VET

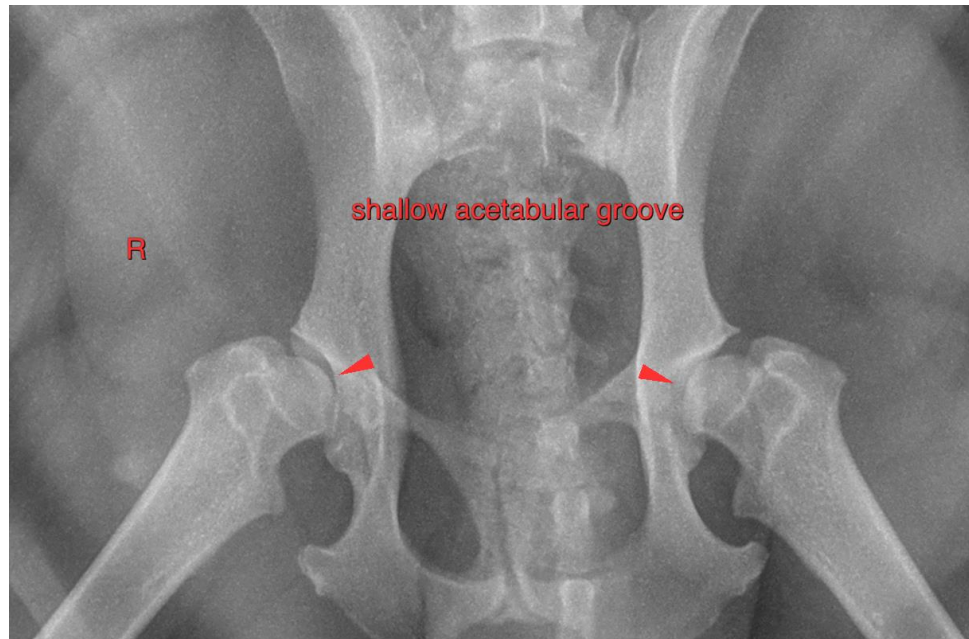
Dr. Ascot

INVOICE

49817

DATE

1-25-22



The information and recommendations provided are based on the images presented by the referring veterinarian/sonographer. No evaluation can be communicated regarding pathology that was not visible in the image/video clips provided.

Thank you for this referral. If the clinical or image interpretation does not parallel your findings or if I can be of any further assistance please contact me.

Sebastian Schaub, Sebastian Schaub, DVM, Dr. med. vet. DipECVDI
sebast.schaub@gmail.com