



## PATIENT

Stormy Vargas

## SPECIES

Canine

## BREED

Pomeranian

## SEX

Female

## AGE

5 Years

## WEIGHT

9.5

## INTERPRETED BY

Sebastian Schaub, DVM  
Dr. med. vet. DipECVDI

## IMAGING PERFORMED BY

Ali

## HOSPITAL NAME

Green Dog Dental and  
Wellness

## REFERRING VET

Dr. Sherry Vertanian

## INVOICE

35589

## DATE

1/24/26

## PRESENTING CLINICAL SIGNS

- APPETITE LOW, NO V. P DID NOT EAT HER KIBBLE YESTERDAY,
- DISTENDED ABDOMEN. O CHANGED DIED 5 DAYS AGO.

Abnormal PE/Chem/CBC/UA Results: ELEVATED PANCREATIC LIPASE \*336 MILD ELAVATION OF ALP \*290 AND ELEVATED MPV,13.8\* REST OF THE BW RESULTS ARE IN NORMAL RANGES

## RADIOGRAPHIC STUDY OF THE ABDOMEN

Radiographs of the abdomen in three imaging planes are provided for review.

## RADIOGRAPHIC FINDINGS

The body condition score is 8/9.

The surrounding bony structures are within normal limits.

No abnormalities of the extraabdominal soft tissues are noted. The abdominal wall is smooth and thin.

The serosal detail is maintained throughout the peritoneal and retroperitoneal space.

The liver is appropriate in position, size and presents uniform opacity.

The splenic head is in the anticipated position and within normal limits for size and opacity. The splenic body and tail are considered normal for position, size, shape and opacity.

Both kidneys are seen and present with normal size, shape, delineation and opacity. The urinary bladder is in its anticipated position. No radiopaque calculi are noted throughout the upper and lower urinary tract.

The stomach is in its anticipated position and presents normal content.

The small intestinal loops are of even diameter and non-dilated, a small amount of gas is seen within the small intestinal loops and considered within normal limits.

The colon is seen in the expected position and presents with appropriate content.

## RADIOGRAPHIC DIAGNOSIS

- Obesity

## INTERPRETATION OF THE FINDINGS & FURTHER RECOMMENDATIONS

The radiographic study reveals no abnormalities, that do explain the presenting clinical signs. There is no evidence of radiopaque foreign material, abnormal gas pattern or signs for gastrointestinal mechanical obstruction.



## PATIENT

Stormy Vargas

## SPECIES

Canine

## BREED

Pomeranian

## SEX

Female

## AGE

5 Years

## WEIGHT

9.5

## INTERPRETED BY

Sebastian Schaub, DVM  
Dr. med. vet. DipECVDI

## IMAGING PERFORMED BY

Ali

## HOSPITAL NAME

Green Dog Dental and  
Wellness

## REFERRING VET

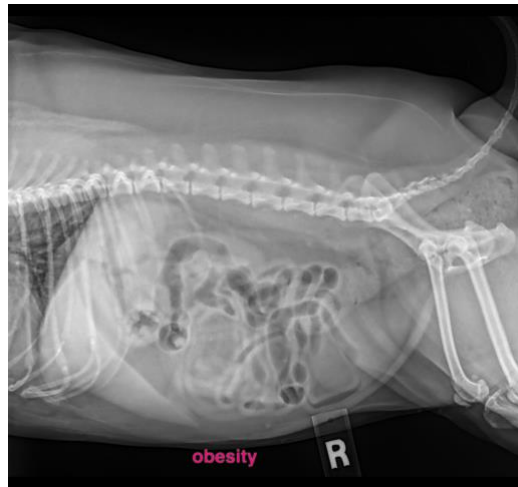
Dr. Sherry Vertanian

## INVOICE

35589

## DATE

1/24/26



**The information and recommendations provided are based on the images presented by the referring veterinarian/sonographer. No evaluation can be communicated regarding pathology that was not visible in the image/video clips provided.**

Thank you for this referral. If the clinical or image interpretation does not parallel your findings or if I can be of any further assistance please contact me.

**Sebastian Schaub**, DVM, Dr. med. vet. DipECVDI  
[info@sonopath.com](mailto:info@sonopath.com)