

**PATIENT**

Daisy Mae Geelan

**SPECIES**

Canine

**BREED**

Jack Russell Terrier

**SEX**

Female Spayed

**AGE**

1 Year, 10 Months

**INTERPRETED BY**Sebastian Schaub, DVM  
Dr. med. vet. DipECVDI**HOSPITAL NAME**Catskill Veterinary  
Services, PLLC**REFERRING VET**

Dr. Daniell Carbone

**INVOICE**

56340

**DATE**

1-24-23

**PRESENTING CLINICAL SIGNS**

Patient had an endoscopy performed at emergency clinic for possible foreign material in esophagus following vomiting, stricture diagnosed and stomach biopsies taken-no results yet for biopsies. Owner has been feeding small, watered down, slow meals and the vomiting has resolved.

Abnormal PE/Chem/CBC/UA Results: CT of neck/chest also performed-submitted separately

**FLUOROSCOPIC STUDY OF THE NECK AND THORAX**

A fluoroscopic study of the neck and thorax during tidal respiration/water intake.

**FLUOROSCOPY FINDINGS**

The pharynx and nasopharynx are aerated and no abnormalities are appreciated during in- and expiration.

The trachea presents normal mild dynamic variation of its diameter during tidal respiration. The course of the trachea is normal, and the margins are smooth.

No pathological narrowing of the principal bronchi is appreciated.

During swallowing no abnormalities can be appreciated – in the study with the time code 12:10, a faint radiopaque bolus is seen in the esophagus.

**FLUOROSCOPY DIAGNOSIS & THERAPEUTIC RECOMMENDATIONS**

- Normal neck & thorax
- No abnormalities during swallowing – esophageal motility appears to be normal.

**INTERPRETATION OF THE FINDINGS & FURTHER RECOMMENDATIONS**

The fluoroscopic study of the neck and thorax presents without abnormalities. If there is strong suspicion for dysphagia, recommend performing a positive contrast swallowing.

**TECHNICAL COMMENTS**

Human hands are seen in the primary beam, please consider radiation safety guidelines!



**PATIENT**

Daisy Mae Geelan

**SPECIES**

Canine

**BREED**

Jack Russell Terrier

**SEX**

Female Spayed

**AGE**

1 Year, 10 Months

**INTERPRETED BY**

Sebastian Schaub, DVM  
Dr. med. vet. DipECVDI

**HOSPITAL NAME**

Catskill Veterinary  
Services, PLLC

**REFERRING VET**

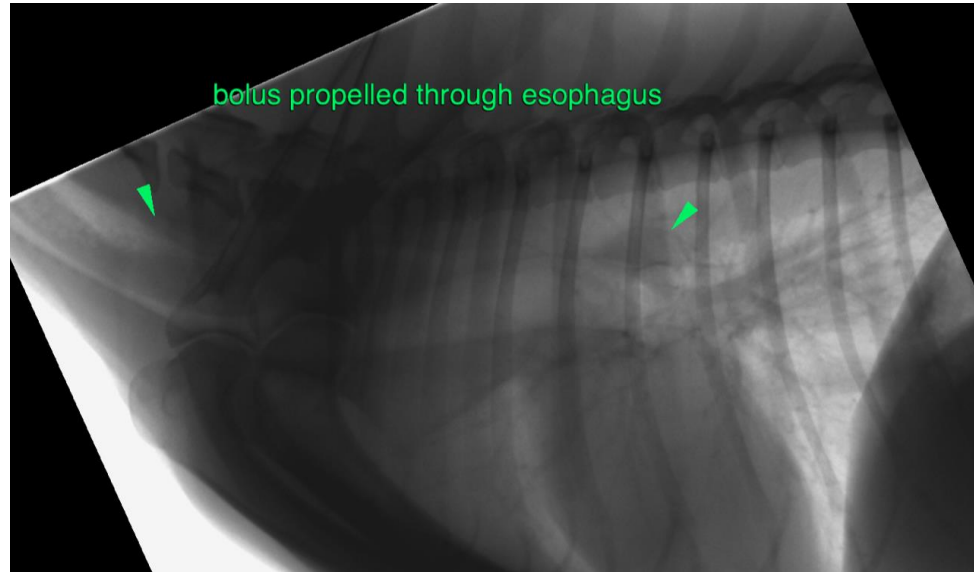
Dr. Daniell Carbone

**INVOICE**

56340

**DATE**

1-24-23



The information and recommendations provided are based on the images presented by the referring veterinarian/sonographer. No evaluation can be communicated regarding pathology that was not visible in the image/video clips provided.

Thank you for this referral. If the clinical or image interpretation does not parallel your findings or if I can be of any further assistance please contact me.

**Sebastian Schaub**, Sebastian Schaub, DVM, Dr. med. vet. DipECVDI  
sebast.schaub@gmail.com