



PATIENT

Abbey Metcalf

PRESENTING CLINICAL SIGNS

Has had diarrhea off and on for the last few days; also noted heavy panting; is acting lethargic today and uncomfortable; did eat today Had a bout of coughing earlier today Gets Rimadyl PRN Abnormal PE/Chem/CBC/UA Results: CBC: band neutrophils suspected, ALT mildly high

SPECIES

Canine

RADIOGRAPHIC STUDY OF THE THORAX

Radiographs of the thorax in three imaging planes are provided for review.

BREED

Border Collie

RADIOGRAPHIC FINDINGS

Multifocal mild spondylosis formation is seen along the thoracic spine. The periarticular bones of both shoulder joints present moderate osteophyte new bone formation. The costal cartilages present advanced degenerative changes.

SEX

FS

The extrathoracic soft tissues present homogeneous without abnormalities.

The heart is of normal size and shape, there is no evidence of cardiac chamber or vascular enlargement. The pulmonary vasculature is within normal limits.

AGE

13 Years

The cranial mediastinum presents the expected soft tissue opacity. The mediastinal width is less than twice the width of the vertebral column at the same level.

The trachea is normal in diameter and presents the anticipated course. The luminal outline of the trachea is smooth.

INTERPRETED BY

Sebastian Schaub, DVM
Dr. med. vet. DipECVDI

The ventral dependent aspects of the lung present a patchy ground glass opacification of the lung parenchyma and moderate peribronchial cuffing is seen in the cranioventral lung field.

The diaphragm is well delineated with even surface and the expected mild cranial bulging of the diaphragmatic cupola.

HOSPITAL NAME

Petroglyph Animal
Hospital

RADIOGRAPHIC DIAGNOSIS

- Ventrally distributed broncho-interstitial lung pattern
- Degenerative osteoarthritis shoulder joints bilaterally
- Spondylosis deformans
- Degenerative changes costal cartilages

REFERRING VET

Alice Ku

INTERPRETATION OF THE FINDINGS & FURTHER RECOMMENDATIONS

The ventrally distributed broncho-interstitial lung pattern of the lung is consistent with broncho-pneumonia, possible due to aspiration. Recommend empirical management of the broncho-pneumonia.

INVOICE

56330

DATE

1-24-23



PATIENT

Abbey Metcalf

SPECIES

Canine

BREED

Border Collie

SEX

FS

AGE

13 Years

INTERPRETED BY

Sebastian Schaub, DVM
Dr. med. vet. DipECVDI

HOSPITAL NAME

Petroglyph Animal
Hospital

REFERRING VET

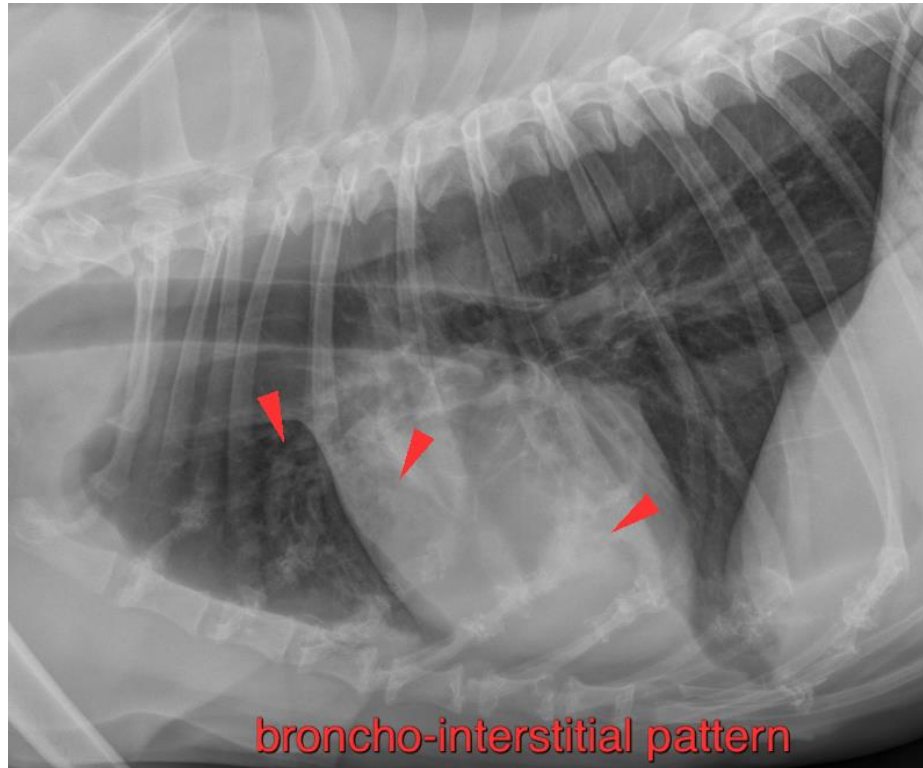
Alice Ku

INVOICE

56330

DATE

1-24-23



The information and recommendations provided are based on the images presented by the referring veterinarian/sonographer. No evaluation can be communicated regarding pathology that was not visible in the image/video clips provided.

Thank you for this referral. If the clinical or image interpretation does not parallel your findings or if I can be of any further assistance please contact me.

Sebastian Schaub, Sebastian Schaub, DVM, Dr. med. vet. DipECVDI
sebast.schaub@gmail.com