

**PATIENT**

Mabel Bowley

PRESENTING CLINICAL SIGNS

Intermittent left foreleg lameness 2 months. Lean musculing both forelimbs, with subtle atrophy over left scapula compared to the right. Elbow joints bilateral mild to moderate effusion palpable in the caudolateral compartment. Elbows painful in extension and during Campbell test (left worse than right).

SPECIES

Canine

COMPUTED TOMOGRAPHY OF THE ELBOW JOINTS

A high resolution plain CT study of the elbow joints is provided for review.

BREED

Goldendoodle

COMPUTED TOMOGRAPHIC FINDINGS

The periarticular bones of the left elbow joint present mild osteophyte new bone formation. At the cranial aspect of the medial coronoid process of the left elbow joint, an isolated, triangular shaped osseous fragment measuring 2.9 x 2.3 x 3.3 mm in size is visible; the base of the medial coronoid process presents moderate sclerosis.

SEX

FS

The right elbow joint presents smooth osseous margins. The medial coronoid process of the right elbow joint presents a homogeneous density with a small osseous spur – possibly isolated – at the tip.

AGE

9 Months

COMPUTED TOMOGRAPHIC DIAGNOSIS

- Fragmented medial coronoid process (FCP) left elbow joint
- Mild degenerative osteoarthritis left elbow joint
- Suspect coronoid disease right elbow joint

INTERPRETED BY

Sebastian Schaub, DVM
Dr. med. vet. DipECVDI

INTERPRETATION OF THE FINDINGS & FURTHER RECOMMENDATIONS

The findings are consistent with mild chronic degenerative joint disease of the left elbow joint due to FCP. The findings of the right elbow joint are equivocal for pathology of the medial coronoid disease. As the findings from the clinical examination are supporting pathology of the medial coronoid process of both elbow joints, arthroscopy is considered beneficial to revise the elbow joints and remove osseous fragments/non-vital tip of the medial coronoid process.

HOSPITAL NAME

Bridgwater
Veterinary Hospital
and Wellness Centre

REFERRING VET

Dr. D. Williams

INVOICE

49780

DATE

1-24-22



PATIENT

Mabel Bowley

SPECIES

Canine

BREED

Goldendoodle

SEX

FS

AGE

9 Months

INTERPRETED BY

Sebastian Schaub, DVM
Dr. med. vet. DipECVDI

HOSPITAL NAME

Bridgwater
Veterinary Hospital
and Wellness Centre

REFERRING VET

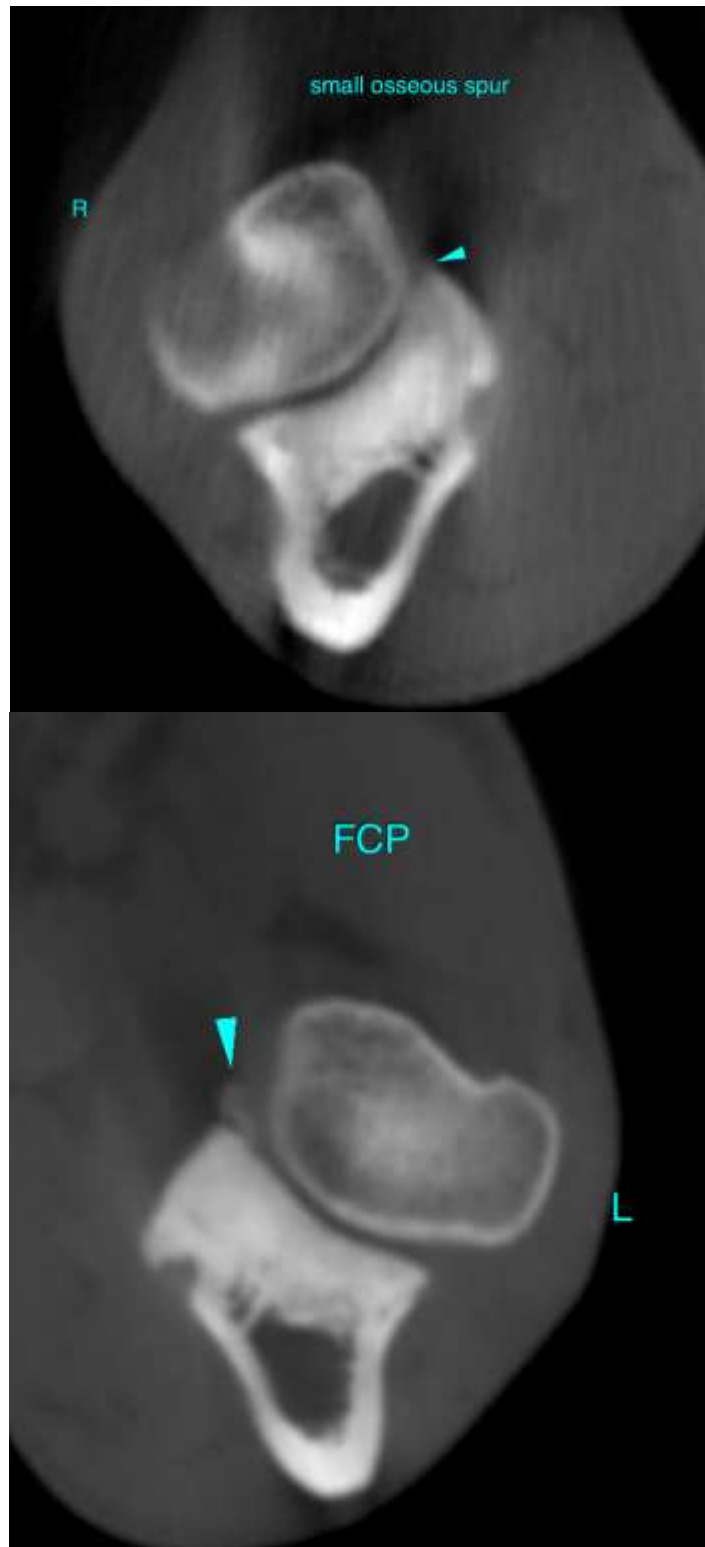
Dr. D. Williams

INVOICE

49780

DATE

1-24-22





PATIENT

Mabel Bowley

SPECIES

Canine

The information and recommendations provided are based on the images presented by the referring veterinarian/sonographer. No evaluation can be communicated regarding pathology that was not visible in the image/video clips provided.

BREED

Goldendoodle

Thank you for this referral. If the clinical or image interpretation does not parallel your findings or if I can be of any further assistance please contact me.

SEX

FS

Sebastian Schaub, Sebastian Schaub, DVM, Dr. med. vet. DipECVDI
sebast.schaub@gmail.com

AGE

9 Months

INTERPRETED BY

Sebastian Schaub, DVM
Dr. med. vet. DipECVDI

HOSPITAL NAME

Bridgwater
Veterinary Hospital
and Wellness Centre

REFERRING VET

Dr. D. Williams

INVOICE

49780

DATE

1-24-22