



PATIENT

Cookie Rincon

PRESENTING CLINICAL SIGNS

Trouble breathing, turns purple. Hx of heart murmur (on meds) and seizures (currently on no meds). Very anxious, also takes alprazolam

SPECIES

Canine

COMPUTED TOMOGRAPHY OF THE SKULL & THORAX

A high resolution pre- and post-contrast CT study of the skull and a post-contrast CT study of the thorax are provided for review.

BREED

Toy Poodle

COMPUTED TOMOGRAPHIC FINDINGS

Skull

The tooth elements 102, 110, 202, 205, 206, 301, 305,311, 401, 405, 406 and 411 are absent. The mesial root of triadan 107 presents a moderate widening of the periodontal space and is perforating the right nasal cavity. A generalized mild horizontal bone loss is visible in all jaw quadrants.

SEX

Female Intact

In the right nasal cavity, a mild amount of fluid attenuating material is attached to the nasal mucosal lining.

AGE

13 Years

The nasal cavity presents the expected aerated spaces between thin & even conchae and turbinates with smooth mucosal lining. There is a moderate.

INTERPRETED BY

Sebastian Schaub, DVM
Dr. med. vet. DipECVDI

Both temporomandibular joints present congruent joint spaces with even subchondral bone surfaces and are considered within normal limits.

HOSPITAL NAME

Mobile Pet Imaging

Both tympanic bullae are aerated, the mucosal lining is not seen, the bony wall is smooth and thin. The external ear canals are within normal limits.

The brain presents no deviation from normal anatomy and symmetry. The brain parenchyma is homogeneous and within normal limits for attenuation and distribution of contrast enhancement. The ventricular system is non-dilated and symmetric.

REFERRING VET

Meaux

The submandibular and medial retropharyngeal lymph nodes are small and elongated with a normal short-to-long-axis-ratio is < 0.5, the attenuation and contrast enhancement pattern is uniform.

Thorax

INVOICE

49779

Multiple wart-like cutaneous lesions are seen along the caudodorsal aspect of the neck and the thoracic wall.

DATE

1-24-22

The sternal, cranial mediastinal and tracheobronchial lymph nodes are small elongated with a normal short-to-long-axis-ratio is < 0.5, the attenuation and contrast enhancement pattern is uniform and considered within normal limits.

The cardiovascular structures including the pulmonary vasculature are within normal limits.



PATIENT

Cookie Rincon

A moderate dorsoventral flattening of the intrathoracic segment of the trachea is visible, with complete collapse level with the crania. The principal bronchi are significantly dorsoventrally flattened.

SPECIES

Canine

The bronchial tree presents with regular branching and tapers uniformly towards the periphery as expected, the bronchial walls are thin and smooth. The bronchus-to-artery ratio is within normal limits.

BREED

Toy Poodle

The volume of the right lung lobes is moderately decreased, and the lung parenchyma of the right lung lobes presents a moderate ground-glass attenuating pattern.

Small incidental gas pockets are seen within the esophageal lumen, there is no evidence of abnormal dilation.

COMPUTED TOMOGRAPHIC DIAGNOSIS

SEX

Female Intact

- Obesity
- Tracheal & bronchial collapse
- Hypoinflation right lung lobes
- Periodontal abscess triadan 107 with oronasal fistula formation
- Mild odontogenic rhinitis
- Multiple absent teeth, see above
- Multiple cutaneous wart like lesions

AGE

13 Years

INTERPRETED BY

Sebastian Schaub, DVM
Dr. med. vet. DipECVDI

INTERPRETATION OF THE FINDINGS & FURTHER RECOMMENDATIONS

The tracheal & bronchial collapse are a plausible explanation for the history of dyspnea. Consider empirical palliative management including weight control. The options of tracheal stenting might be discussed with surgeon/internal medicine, but the therapy success is degraded by the bronchial collapse.

HOSPITAL NAME

Mobile Pet Imaging

REFERRING VET

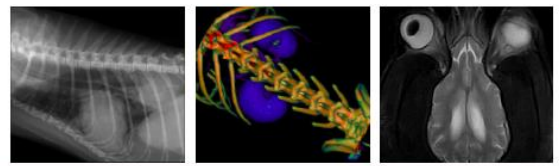
Meaux

INVOICE

49779

DATE

1-24-22



PATIENT

Cookie Rincon

SPECIES

Canine

BREED

Toy Poodle

SEX

Female Intact

AGE

13 Years

INTERPRETED BY

Sebastian Schaub, DVM
Dr. med. vet. DipECVDI

HOSPITAL NAME

Mobile Pet Imaging

REFERRING VET

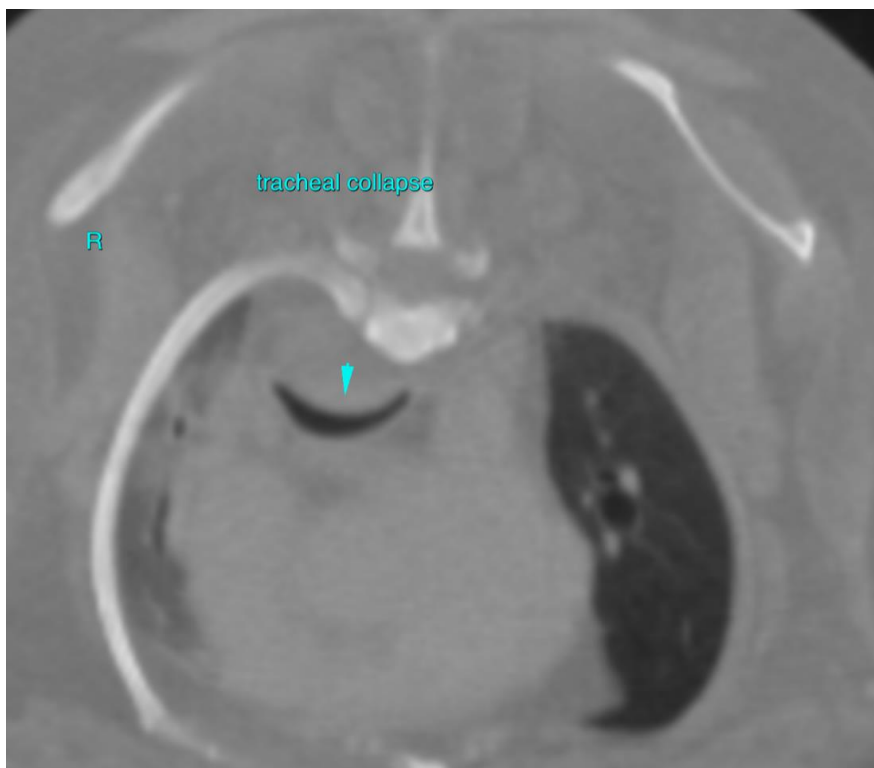
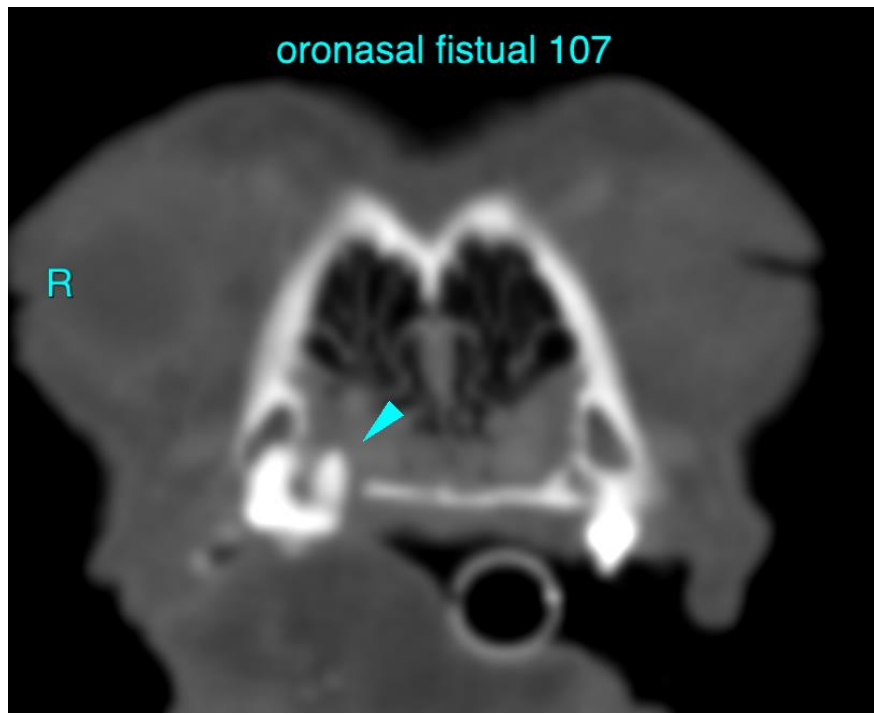
Meaux

INVOICE

49779

DATE

1-24-22





PATIENT

Cookie Rincon

SPECIES

Canine

BREED

Toy Poodle

SEX

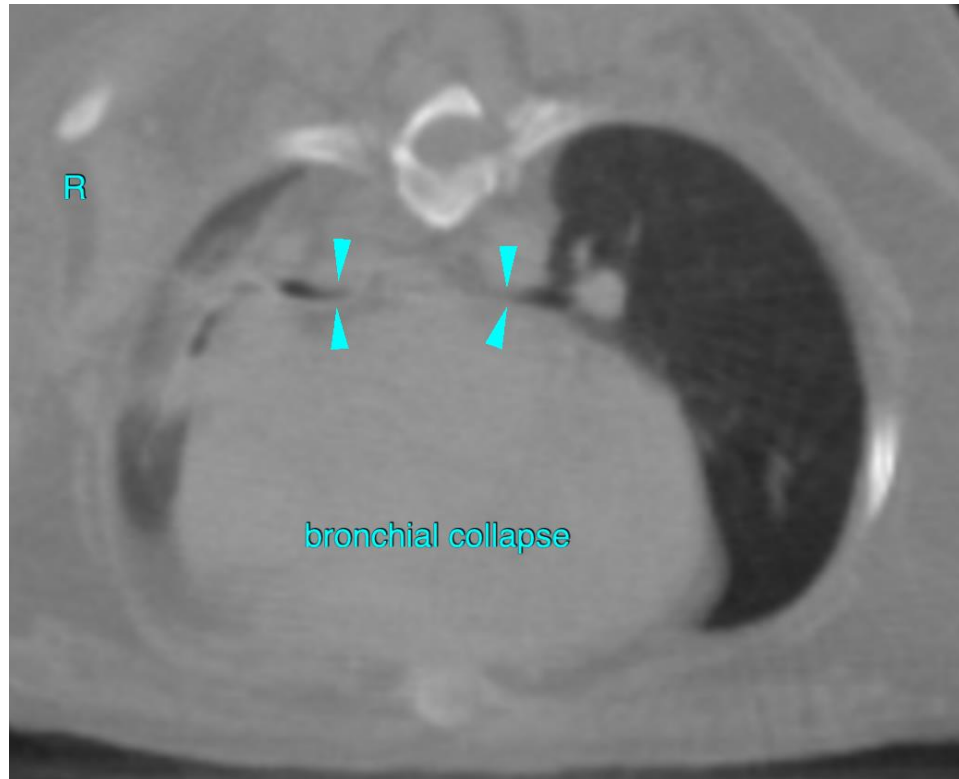
Female Intact

AGE

13 Years

INTERPRETED BY

Sebastian Schaub, DVM
Dr. med. vet. DipECVDI



HOSPITAL NAME

Mobile Pet Imaging

REFERRING VET

Meaux

INVOICE

49779

DATE

1-24-22

The information and recommendations provided are based on the images presented by the referring veterinarian/sonographer. No evaluation can be communicated regarding pathology that was not visible in the image/video clips provided.

Thank you for this referral. If the clinical or image interpretation does not parallel your findings or if I can be of any further assistance please contact me.

Sebastian Schaub, Sebastian Schaub, DVM, Dr. med. vet. DipECVDI
sebast.schaub@gmail.com