



PATIENT

Mochi Yavich

SPECIES

Canine

BREED

Shih Tzu

SEX

Neutered Male

AGE

5 Years

WEIGHT

16.9 Pounds

INTERPRETED BY

Sebastian Schaub, DVM
Dr. med. vet. DipECVDI

IMAGING PERFORMED BY

Dr. Amanda Causey

HOSPITAL NAME

Heron Lakes AH

REFERRING VET

Dr. Lera

INVOICE

35580

DATE

1/23/26

PRESENTING CLINICAL SIGNS

History of chronic ear infections.

COMPUTED TOMOGRAPHIC STUDY OF THE SKULL

A high resolution pre- and post-contrast CT study of the skull is provided for review.

COMPUTED TOMOGRAPHIC FINDINGS

The skull has a brachycephalic conformation with significant crowding and rotation of the maxillary premolar teeth.

The tooth elements 305, 311, 405 and 411 are absent.

The nasal cavity presents the expected aerated spaces between thin & even conchae and turbinates with smooth mucosal lining.

Both temporomandibular joints present congruent joint spaces with even subchondral bone surfaces and are considered within normal limits.

Both tympanic bullae are aerated, the mucosal lining is not seen, the bony wall is smooth and thin. The external ear canals are within normal limits.

The brain presents no deviation from normal anatomy and symmetry. The brain parenchyma is homogeneous and within normal limits for attenuation and distribution of contrast enhancement. The ventricular system is non-dilated and symmetric.

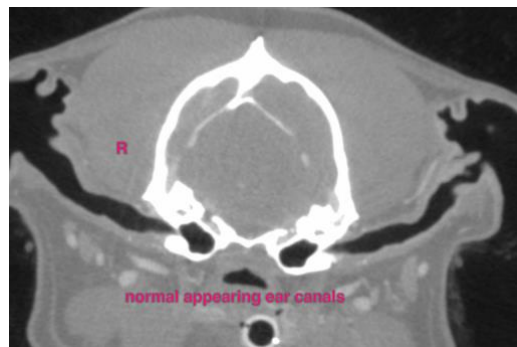
The submandibular and medial retropharyngeal lymph nodes are small and elongated with a normal short-to-long-axis-ratio is < 0.5, the attenuation and contrast enhancement pattern is uniform.

COMPUTED TOMOGRAPHIC DIAGNOSIS

- Absent triadan 305, 311, 404 and 411
- No evidence of otitis media

INTERPRETATION OF THE FINDINGS & FURTHER RECOMMENDATIONS

The CT study reveals no clinically relevant abnormalities. The ear canals present without overt abnormalities and there is no evidence of a mass/polypoid lesion in the ear canals.



The information and recommendations provided are based on the images presented by the



PATIENT

Mochi Yavich

SPECIES

Canine

BREED

Shih Tzu

SEX

Neutered Male

AGE

5 Years

WEIGHT

16.9 Pounds

INTERPRETED BY

Sebastian Schaub, DVM
Dr. med. vet. DipECVDI

**IMAGING
PERFORMED BY**

Dr. Amanda Causey

HOSPITAL NAME

Heron Lakes AH

REFERRING VET

Dr. Lera

INVOICE

35580

DATE

1/23/26

referring veterinarian/sonographer. No evaluation can be communicated regarding pathology that was not visible in the image/video clips provided.

Thank you for this referral. If the clinical or image interpretation does not parallel your findings or if I can be of any further assistance please contact me.

Sebastian Schaub, DVM, Dr. med. vet. DipECVDI
info@sonopath.com