



PATIENT

Minnie Barroso

SPECIES

Canine

BREED

Chihuahua

SEX

Female

AGE

8 Years

WEIGHT

11.7 Pounds

INTERPRETED BY

Sebastian Schaub, DVM
Dr. med. vet. DipECVDI

IMAGING PERFORMED BY

Monika

HOSPITAL NAME

Westchester AH

REFERRING VET

Dr. Randy Dominguez

INVOICE

35583

DATE

1/13/26

PRESENTING CLINICAL SIGNS

History: Presented from Miami Animal Clinic. Owner reported Dog is screaming on pain of unknown Origin so far at nighttime. P.E unremarkable.

Abnormal PE/Chem/CBC/UA Results: Unremarkable

COMPUTED TOMOGRAPHIC STUDY OF THE CERVICAL, THORACIC AND LUMBAR SPINE

A high resolution pre- and post-contrast CT study of the entire spine is provided for review.

COMPUTED TOMOGRAPHIC FINDINGS

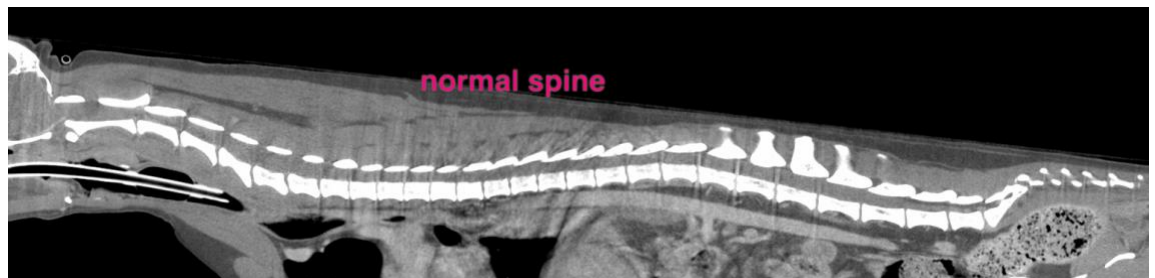
The osseous and soft tissue structures of the cervical, thoracic and lumbar spine reveal no abnormalities. The dural tube along the entire spine has the expected diameter and attenuation behavior. Post contrast administration no pathological contrast uptake is appreciated.

COMPUTED TOMOGRAPHIC DIAGNOSIS

- Normal cervical spine
- Normal thoracic spine
- Normal lumbar spine

INTERPRETATION OF THE FINDINGS & FURTHER RECOMMENDATIONS

The CT study reveals no abnormalities and an underlying cause for the described clinical signs cannot be specified – there is no evidence of an extradural nor intradural lesion. If there is strong suspicion for underlying compressive myelopathy or intradural lesions, workup can be complemented by a myelographic CT study or MRI study of the spine.



The information and recommendations provided are based on the images presented by the referring veterinarian/sonographer. No evaluation can be communicated regarding pathology that was not visible in the image/video clips provided.

Thank you for this referral. If the clinical or image interpretation does not parallel your findings or if I can be of any further assistance please contact me.

Sebastian Schaub, DVM, Dr. med. vet. DipECVDI
info@sonopath.com