

PATIENT

Ellie Redmond

SPECIES

Canine

BREED

Golden Doodle

SEX

Spayed Female

AGE

7 Years 11 Months

WEIGHT

13.7 Pounds

INTERPRETED BY

Sebastian Schaub, DVM
Dr. med. vet. DipECVDI

IMAGING PERFORMED BY

Dr. Causey

HOSPITAL NAME

Heron Lakes AH

REFERRING VET

Dr. Lera

INVOICE

35587

DATE

1/23/26

PRESENTING CLINICAL SIGNS

History: Persistent cough, no blood or mucous. Intermittent vomiting. Partially responsive to antibiotics.

Abnormal PE/Chem/CBC/UA Results: BW WNL, Heartworm test negative.

FLUOROSCOPIC STUDY OF THE SKULL/NECK AND THORAX

A fluoroscopic study of the skull, neck and thorax during tidal respiration and a positive contrast barium swallowing study is provided for review.

FLUOROSCOPY FINDINGS

The trachea presents the expected diameter throughout with the expected minimal alteration of the tracheal height between in- and expiration.

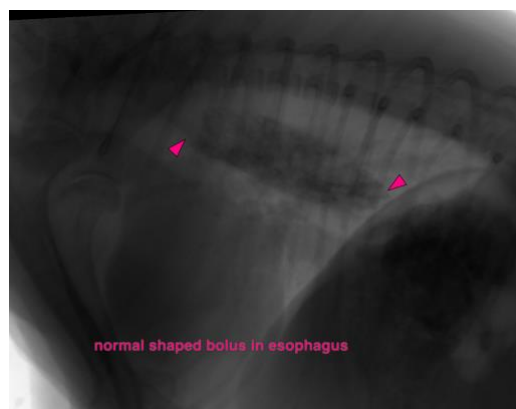
Normal apprehension of the food and a physiological pharyngeal phase are appreciated. The esophagus presents a physiological motility. The boluses are propelled into the stomach by primary waves. The boluses in the esophagus present a physiological shape with a convex caudal border and is tapering in the cranial aspect. The boluses are propelled by primary waves through the cardia into the stomach. No reflux of gastric content into the esophagus is appreciated.

FLUOROSCOPY DIAGNOSIS & THERAPEUTIC RECOMMENDATIONS

- Normal swallowing study
- Normal trachea

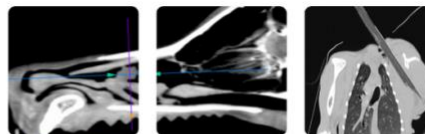
INTERPRETATION OF THE FINDINGS & FURTHER RECOMMENDATIONS

The fluoroscopic study reveals no signs of esophageal dysmotility nor evidence of pathology of the pharyngeal phase of swallowing.



The information and recommendations provided are based on the images presented by the referring veterinarian/sonographer. No evaluation can be communicated regarding pathology that was not visible in the image/video clips provided.

Thank you for this referral. If the clinical or image interpretation does not parallel your findings or if I



PATIENT

Ellie Redmond

SPECIES

Canine

BREED

Golden Doodle

SEX

Spayed Female

AGE

7 Years 11 Months

WEIGHT

13.7 Pounds

INTERPRETED BY

Sebastian Schaub, DVM
Dr. med. vet. DipECVDI

**IMAGING
PERFORMED BY**

Dr. Causey

HOSPITAL NAME

Heron Lakes AH

REFERRING VET

Dr. Lera

INVOICE

35587

DATE

1/23/26

can be of any further assistance please contact me.

Sebastian Schaub, DVM, Dr. med. vet. DipECVDI
info@sonopath.com