



PATIENT

Waffle Chan

SPECIES

Canine

BREED

Poodle

SEX

Male

AGE

4Y

WEIGHT

5.9

INTERPRETED BY

Sebastian Schaub, DVM
Dr. med. vet.
DipECVDI

IMAGING PERFORMED BY

Hollie Sharp

HOSPITAL NAME

Animal Trust -
Ellesmere Port

REFERRING VET

Dylan Payne

INVOICE

73439

DATE

1-22-26

PRESENTING CLINICAL SIGNS

History:

- Acute onset of shoulder pain.
- limping on/off. Non-weight bearing during these episodes.
- very mild lameness on the right forelimb. Muscle atrophy over the right scapula. Pain elicited specially on fully extension of the right shoulder. Painful on palpation of the right shoulder. No other abnormalities seen.

COMPUTED TOMOGRAPHY OF THE SHOULDER JOINTS

A high resolution plain and positive contrast arthrography CT study of the right shoulder joint is provided for review.

COMPUTED TOMOGRAPHIC FINDINGS

The osseous and surrounding soft tissue structures of the left shoulder joint reveal no abnormalities.

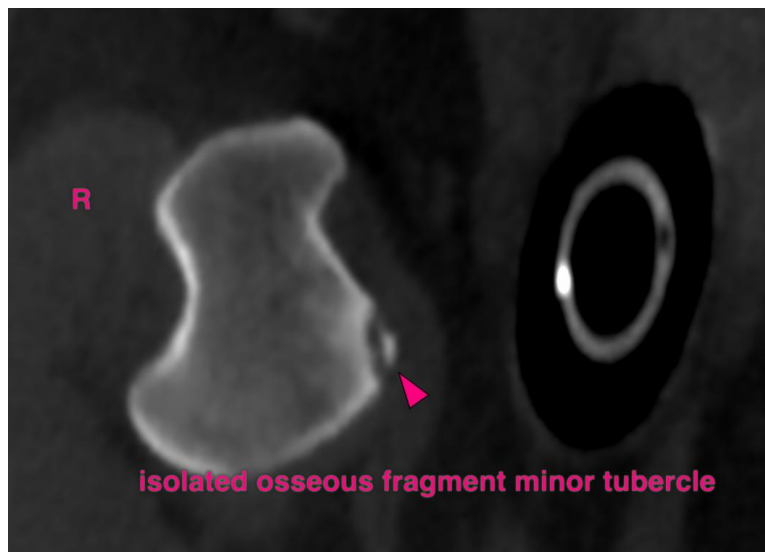
Along the medial surface of the scapular neck, smooth solid periosteal new bone formation is appreciated. At minor tubercle of the right humerus, an isolated osseous fragment with a corresponding fragment bed is seen; measuring 2.1 x 1.5 x 3.1 mm. Post intrathecal contrast administration into the right shoulder joint, the bicipital tendon has smooth margins and appears homogenous. The subscapularis tendon has a feathered appearance with interspersed contrast media.

COMPUTED TOMOGRAPHIC DIAGNOSIS

- Tendinopathy right subscapularis tendon with potential small avulsion fragment of the minor tubercle of the right humerus

INTERPRETATION OF THE FINDINGS & FURTHER RECOMMENDATIONS

The CT findings are for partial rupture of the right subscapularis tendon – arthroscopy can be performed for specification.





PATIENT

Waffle Chan

SPECIES

Canine

BREED

Poodle

SEX

Male

AGE

4Y

WEIGHT

5.9

INTERPRETED BY

Sebastian Schaub, DVM
Dr. med. vet.
DipECVDI

IMAGING PERFORMED BY

Hollie Sharp

HOSPITAL NAME

Animal Trust -
Ellesmere Port

REFERRING VET

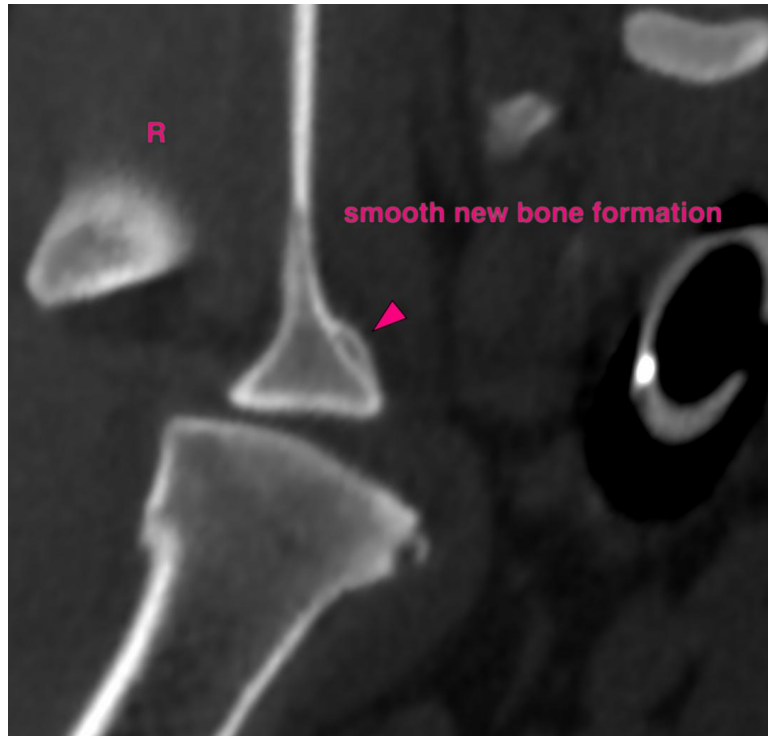Dylan Payne

INVOICE

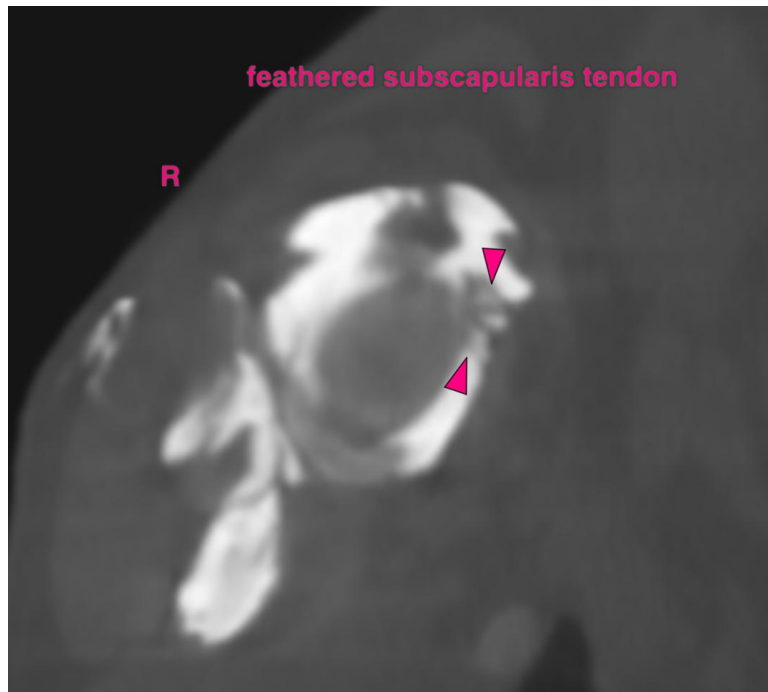
73439

DATE

1-22-26



smooth new bone formation



feathered subscapularis tendon



PATIENT

Waffle Chan

The information and recommendations provided are based on the images presented by the referring veterinarian/sonographer. No evaluation can be communicated regarding pathology that was not visible in the image/video clips provided.

SPECIES

Canine

Thank you for this referral. If the clinical or image interpretation does not parallel your findings or if I can be of any further assistance please contact me.

BREED

Poodle

Sebastian Schaub, Sebastian Schaub, DVM, Dr. med. vet. DipECVDI

info@sonopath.com

SEX

Male

AGE

4Y

WEIGHT

5.9

INTERPRETED BY

Sebastian Schaub, DVM
Dr. med. vet.
DipECVDI

IMAGING PERFORMED BY

Hollie Sharp

HOSPITAL NAME

Animal Trust -
Ellesmere Port

REFERRING VET

Dylan Payne

INVOICE

73439

DATE

1-22-26