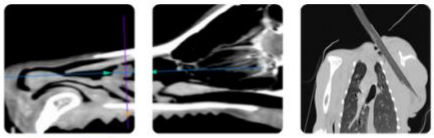

Teleradiology
Educational Teleconsultation Services™

PATIENT
Pluma Yagley

SPECIES
Canine

BREED
Pug

SEX
Female

AGE
1 Year

WEIGHT
11 Pounds

INTERPRETED BY
Sebastian Schaub, DVM
Dr. med. vet. DipECVDI

IMAGING PERFORMED BY
Dr. Laura Baumert

HOSPITAL NAME
Wilson VH

REFERRING VET
Dr. Amy Hawkins

INVOICE
35568

DATE
1/22/26

PRESENTING CLINICAL SIGNS

Pet presented for weakness/ lethargy that progressed to restlessness and pacing, V+, D+ and acute collapse. BW revealed increased LE, including pre and post prandial bile acids, and low creat. Abdominal US revealed microhepatica. A CT was advised to screen for a PSS.

Abnormal PE/Chem/CBC/UA Results: ALT 1685 (10-125), Creat 0.4 (0.5-1.8), ALP 425 (23-212) Pre prandial bile acids 127 Post prandial bile acids >180

COMPUTED TOMOGRAPHIC STUDY OF THE ABDOMEN

A high resolution pre- and post-contrast CT study of the abdomen is provided for review.

COMPUTED TOMOGRAPHIC FINDINGS

The serosal fat presents normal attenuation behavior. There is no evidence of peritoneal effusion or peritonitis.

Both kidneys present within normal limits for size, shape and organ architecture. After contrast administration a bilaterally symmetric and uniform nephro- and pyelogram is noted.

The adrenal glands are within normal limits for size, shape and organ architecture.

The spleen presents with normal shape, even surface, uniformly attenuating parenchyma and homogeneous contrast enhancement, unremarkable.

The hepatic volume is mildly decreased, and the gastric axis is mildly oriented cranially. The hepatic parenchyma is uniform soft tissue attenuating and contrast enhancing.

The left gastric vein is dilated, measuring approximately 2.5x the diameter of the paralleling portal vein at the same level. The portal vein cranial to the splenic vein is tapering in its course cranially and the intrahepatic branches of the portal vein can be appreciated up to the 3rd order vessels. Originating from the dilated left gastric vein, an anomalous vascular loop is coursing cranially and dorsally – beyond the gastric fundus – draining into the dilated azygos vein. The anomalous vascular loop originating from the left gastric vein is measuring 10.8 mm in diameter. The pancreas is evenly contoured; the pancreatic parenchyma is homogeneous and presents uniform contrast enhancement.

The position, delineation, wall and content of the gastrointestinal tract are considered within normal limits throughout.

The bony and surrounding soft tissue structures reveal no abnormalities.

COMPUTED TOMOGRAPHIC DIAGNOSIS

- Congenital single extrahepatic portosystemic shunt, left gastric vein to azygos vein (porto-azygos shunt)
- Mild microhepatica

INTERPRETATION OF THE FINDINGS & FURTHER RECOMMENDATIONS

The CT study is consistent with a congenital single extrahepatic portosystemic shunt (left gastric vein to azygos vein).

PATIENT

Pluma Yagley

SPECIES

Canine

BREED

Pug

SEX

Female

AGE

1 Year

WEIGHT

11 Pounds

INTERPRETED BY

Sebastian Schaub, DVM
Dr. med. vet. DipECVDI

IMAGING PERFORMED BY

Dr. Laura Baumert

HOSPITAL NAME

Wilson VH

REFERRING VET

Dr. Amy Hawkins

INVOICE

35568

DATE

1/22/26

Surgical intervention by a slow progressive closure technique (ameroid constrictor, cellophane banding) is the therapy of choice. Ligation of the shunt vessel may be feasible as well if there is no evidence of portal hypertension during digital compression of the shunting vessel. Empirical treatment until surgery along with feeding of a hepatic diet is recommended

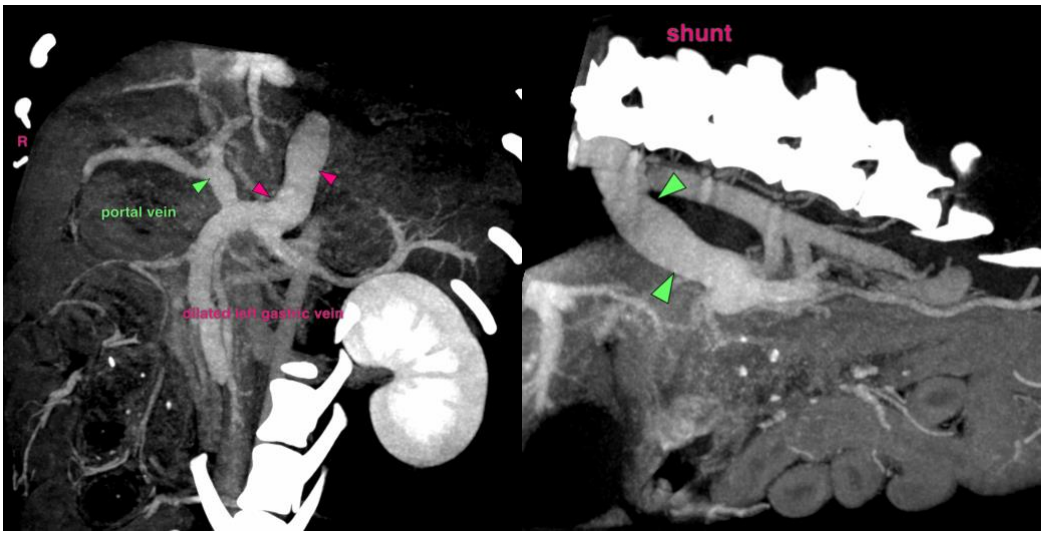

The information and recommendations provided are based on the images presented by the referring veterinarian/sonographer. No evaluation can be communicated regarding pathology that was not visible in the image/video clips provided.

Thank you for this referral. If the clinical or image interpretation does not parallel your findings or if I can be of any further assistance please contact me.

Sebastian Schaub, DVM, Dr. med. vet. DipECVDI
info@sonopath.com