



PATIENT PRESENTING CLINICAL SIGNS

Tigger Maben
 Acute onset of respiratory distress that occurred following three days of coughing.
 Indoor/outdoor cat.
 Abnormal PE/Chem/CBC/UA Results: n/a

SPECIES RADIOGRAPHIC STUDY OF THE THORAX

Feline
 Radiographs of the thorax in three imaging planes are provided for review.

RADIOGRAPHIC FINDINGS

BREED
 DSH
 The thoracic volume is increased, and the ribs are diverging, the thorax has a barrel chested conformation with loss of the normal reverse v-shaped conformation.

The extrathoracic soft tissues present homogeneous without abnormalities.

SEX
 MN
 The heart is of normal size and shape, there is no evidence of cardiac chamber or vascular enlargement. The pulmonary vasculature is within normal limits.

The trachea is normal in diameter and presents the anticipated course. The luminal outline of the trachea is smooth.

AGE
 6 Years
 Generalized increased visibility of the bronchial walls is seen.

The lung parenchyma presents the expected architecture and generalized decreased radiopacity.

INTERPRETED BY
 Sebastian Schaub, DVM
 Dr. med. vet. DipECVDI
 The diaphragm is flattened and an increased distance between the heart and the diaphragm is appreciated. In the VD view, scalloping of the diaphragm is noted.

RADIOGRAPHIC DIAGNOSIS

- Bronchial lung pattern with significant air-trapping

HOSPITAL NAME INTERPRETATION OF THE FINDINGS & FURTHER RECOMMENDATIONS

Petroglyph Animal Hospital
 The radiographic study is consistent with feline asthma with secondary hyperinflation of the lung due to air-trapping. The finding is a plausible explanation for the presenting clinical signs. Recommend empirical management, for long-term treatment the use of an asthma-inhaler is considered beneficial.

REFERRING VET

Dr. Alice Ku

INVOICE

56296

DATE

1-22-23



PATIENT

Tigger Maben

SPECIES

Feline

BREED

DSH

SEX

MN

AGE

6 Years

INTERPRETED BY

Sebastian Schaub, DVM
Dr. med. vet. DipECVDI

HOSPITAL NAME

Petroglyph Animal
Hospital

REFERRING VET

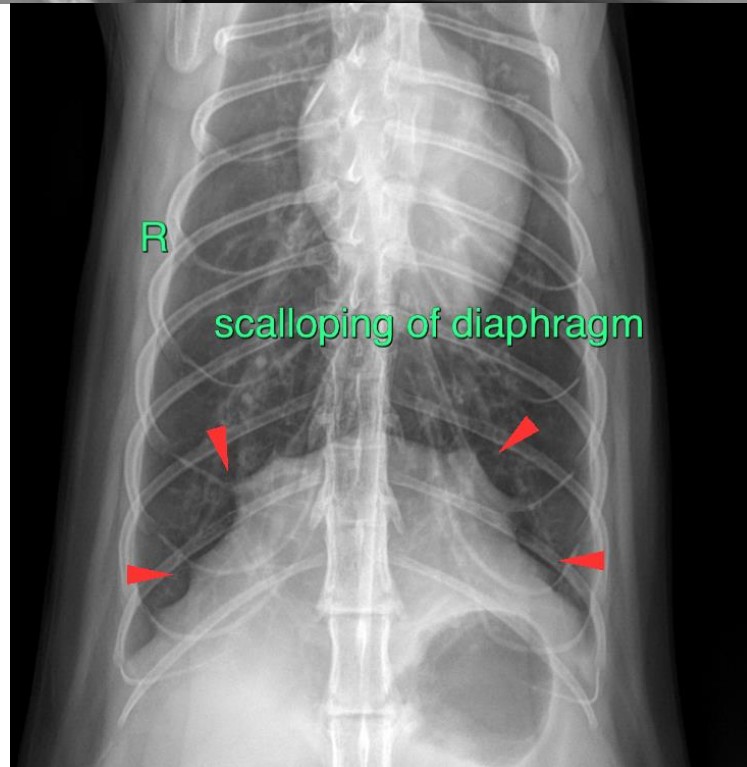
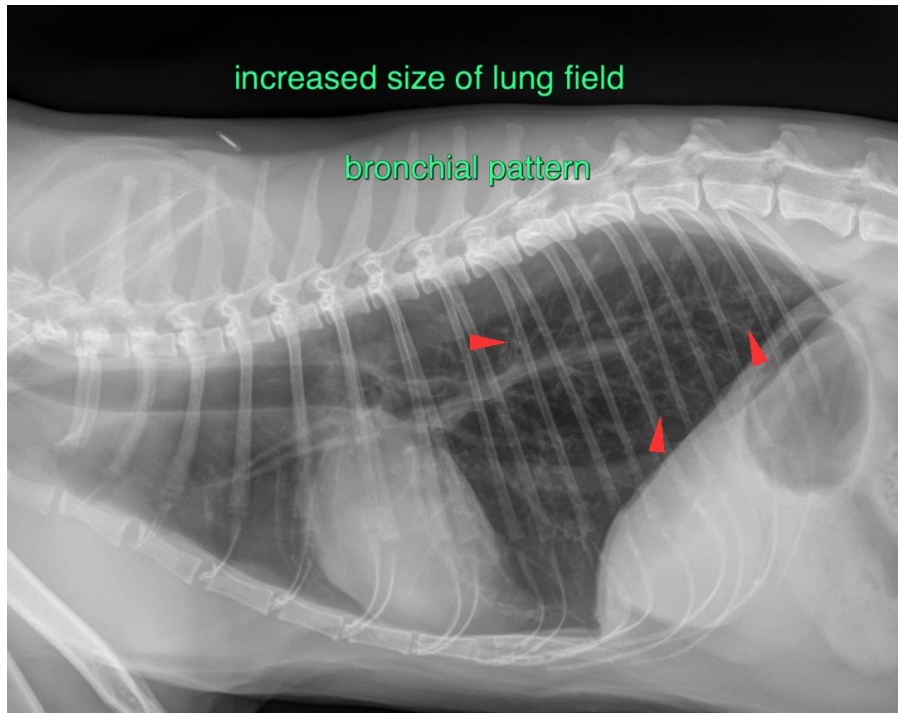
Dr. Alice Ku

INVOICE

56296

DATE

1-22-23





PATIENT

Tigger Maben

The information and recommendations provided are based on the images presented by the referring veterinarian/sonographer. No evaluation can be communicated regarding pathology that was not visible in the image/video clips provided.

SPECIES

Feline

Thank you for this referral. If the clinical or image interpretation does not parallel your findings or if I can be of any further assistance please contact me.

BREED

DSH

Sebastian Schaub, Sebastian Schaub, DVM, Dr. med. vet. DipECVDI
sebast.schaub@gmail.com

SEX

MN

AGE

6 Years

INTERPRETED BY

Sebastian Schaub, DVM
Dr. med. vet. DipECVDI

HOSPITAL NAME

Petroglyph Animal
Hospital

REFERRING VET

Dr. Alice Ku

INVOICE

56296

DATE

1-22-23