



PATIENT

Bubba Summit Rescue

PRESENTING CLINICAL SIGNS

Rescue dog originating from Texas put on doxycycline and carprofen.

SPECIES

Canine

RADIOGRAPHIC STUDY OF THE PELVIS

Radiographs of the pelvis in two orthogonal imaging planes are provided for review.

BREED

Mixed

RADIOGRAPHIC FINDINGS

The right femoral head presents a significantly decreased size and is irregular and misshapen. The right femoral head has a heterogeneous appearance with zones of sclerosis/osteophyte new bone formation and zones with osteolysis. The right acetabular groove presents with moderate periarticular new bone formation, is shallow and is filled with osseous material.

The left coxofemoral joint presents without abnormalities.

SEX

Neutered Male

In the subcutaneous tissue of the ventral abdominal wall, a metal opaque air-gun pellet is seen.

RADIOGRAPHIC DIAGNOSIS

- Advanced chronic degenerative osteoarthritis right coxofemoral joint with chronic remodeling of the right femoral head.
- Air-gun pellet subcutaneous tissue ventral abdominal wall

AGE

2 Years

INTERPRETATION OF THE FINDINGS & FURTHER RECOMMENDATIONS

The changes of the right femoral head are likely a sequela to preceding traumatic insult – possibly during growth – with advanced degenerative osseous remodeling of the right femoral head. Theoretically chronic infectious arthritis is a consideration as well, but I would consider this less likely – a synovial tap of the right coxofemoral joint can be used to rule out infection. Due to the advanced degenerative changes, the chances of right-sided femoral head ostectomy or right-sided hip endoprosthesis should be discussed with orthopedic surgeon.

INTERPRETED BY

Sebastian Schaub, DVM
Dr. med. vet. DipECVDI

HOSPITAL NAME

Summit Dog & Cat
Hospital

REFERRING VET

Dr. Lepkowski

INVOICE

56294

DATE

1-22-23



PATIENT

Bubba Summit Rescue

SPECIES

Canine

BREED

Mixed

SEX

Neutered Male

AGE

2 Years

INTERPRETED BY

Sebastian Schaub, DVM
Dr. med. vet. DipECVDI

HOSPITAL NAME

Summit Dog & Cat
Hospital

REFERRING VET

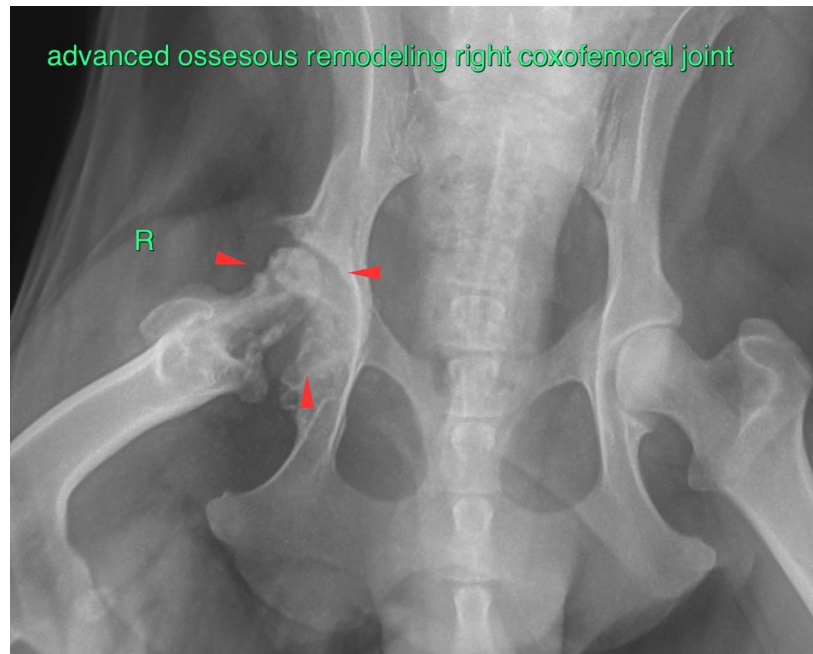
Dr.Lepkowski

INVOICE

56294

DATE

1-22-23



The information and recommendations provided are based on the images presented by the referring veterinarian/sonographer. No evaluation can be communicated regarding pathology that was not visible in the image/video clips provided.

Thank you for this referral. If the clinical or image interpretation does not parallel your findings or if I can be of any further assistance please contact me.

Sebastian Schaub, Sebastian Schaub, DVM, Dr. med. vet. DipECVDI
sebast.schaub@gmail.com