



PATIENT

Bailey Bernard

SPECIES

Canine

BREED

Cavalier King Charles
Spaniel

SEX

Male

AGE

7Y

WEIGHT

12.85kg

INTERPRETED BY

Sebastian Schaub, DVM
Dr. med. vet.
DipECVDI

IMAGING PERFORMED BY

Colin Boyd

HOSPITAL NAME

Aggie Animal Dental
Center

REFERRING VET

Colin Boyd

INVOICE

73433

DATE

1-21-26

PRESENTING CLINICAL SIGNS

History:

- Antibiotic responsive right sided facial swelling, first observed on 11/11/25. Swelling has not been recurrent since abs.
- Presented today for CBCT and further investigation. No evidence of periapical disease but abnormal bone changes noted dorsal to RmaxP4 distal root/RmaxM1. No soft tissue lesions or draining tracts were identified.

COMPUTED TOMOGRAPHY OF THE SKULL

A high resolution plain CT study of the skull is provided for review.

COMPUTED TOMOGRAPHIC FINDINGS

Triadan 305 and 405 are retained within the alveolar bone. Triadan 202 presents a widened pulp cavity and periapical periodontal space with perforation of the left nasal cavity.

The nasal cavity presents the expected aerated spaces between thin & even conchae and turbinates with smooth mucosal lining.

Both temporomandibular joints present congruent joint spaces with even subchondral bone surfaces and are considered within normal limits.

Both tympanic bullae are obliterated by soft tissue attenuating material. The osseous wall of the tympanic bullae is mildly thickened and smooth. The external ear canals are within normal limits.

The submandibular and medial retropharyngeal lymph nodes are small and elongated with a normal short-to-long-axis-ratio is < 0.5, the attenuation and contrast enhancement pattern is uniform.

COMPUTED TOMOGRAPHIC DIAGNOSIS

- Periodontal abscess triadan 202 with perforation of the left nasal cavity
- Bilateral otitis media – likely primary secretory

INTERPRETATION OF THE FINDINGS & FURTHER RECOMMENDATIONS

No abnormalities are appreciated that do explain the previous right sided facial swelling – there is no evidence of underlying dental disease.



PATIENT

Bailey Bernard

SPECIES

Canine

BREED

Cavalier King Charles
Spaniel

SEX

Male

AGE

7Y

WEIGHT

12.85kg

INTERPRETED BY

Sebastian Schaub, DVM
Dr. med. vet.
DipECVDI

IMAGING PERFORMED BY

Colin Boyd

HOSPITAL NAME

Aggie Animal Dental
Center

REFERRING VET

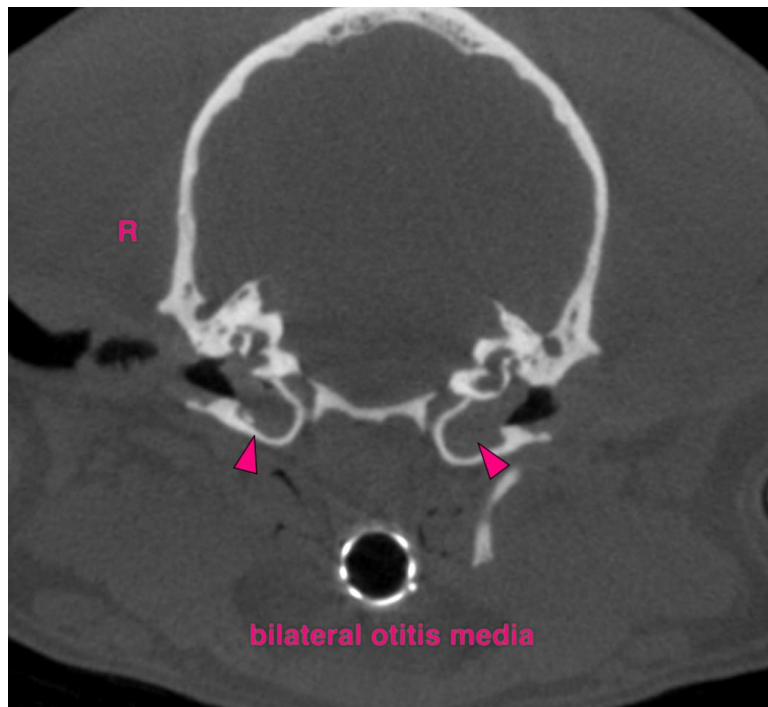
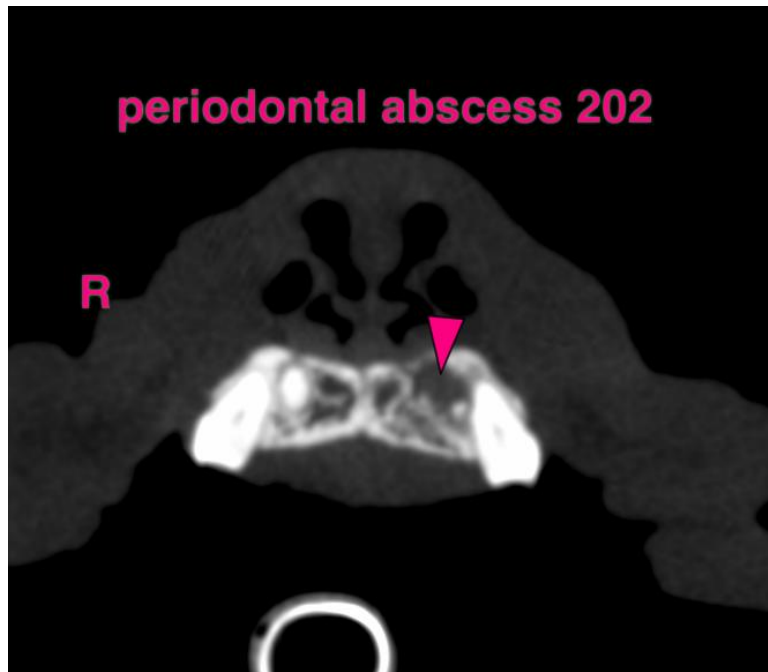Colin Boyd

INVOICE

73433

DATE

1-21-26





PATIENT

Bailey Bernard

SPECIES

Canine

BREED

Cavalier King Charles
Spaniel

SEX

Male

AGE

7Y

WEIGHT

12.85kg

INTERPRETED BY

Sebastian Schaub, DVM
Dr. med. vet.
DipECVDI

IMAGING PERFORMED BY

Colin Boyd

HOSPITAL NAME

Aggie Animal Dental
Center

REFERRING VET

Colin Boyd

INVOICE

73433

DATE

1-21-26

The information and recommendations provided are based on the images presented by the referring veterinarian/sonographer. No evaluation can be communicated regarding pathology that was not visible in the image/video clips provided.

Thank you for this referral. If the clinical or image interpretation does not parallel your findings or if I can be of any further assistance please contact me.

Sebastian Schaub, Sebastian Schaub, DVM, Dr. med. vet. DipECVDI
info@sonopath.com