



## PATIENT

Nolan Ferguson

## SPECIES

Feline

## BREED

Domestic Shorthair

## SEX

Male Neutered

## AGE

15Y, 5M, 3D

## WEIGHT

11.10lbs

## INTERPRETED BY

Sebastian Schaub, DVM  
Dr. med. vet.  
DipECVDI

## IMAGING PERFORMED BY

Joseph D'Abbraccio,  
DVM

## HOSPITAL NAME

Catskill Veterinary  
Services, PLLC

## REFERRING VET

Joseph D'Abbraccio,  
DVM

## INVOICE

73387

## DATE

1-20-26

## PRESENTING CLINICAL SIGNS

### History:

- Owner reports third eyelid elevation, sneezing, watery eyes, and decreased appetite beginning around November. Px has been scratching at the side of the face, resulting in a wound on the ear that was treated and healed. Owner observed bleeding from the mouth near the lip the previous day, possibly from catching it on something. Px is currently only on gabapentin for this visit; previously treated with three different antibiotics, with improvement noted on the most recent antibiotic. Px is indoor only. Owner notes patient has anxiety-related defecation when traveling in the carrier, with normal urination. Owner states patient has not lost visible weight but has been as high as 17 pounds in the past and has averaged 12-14 pounds prior to current weight of 11.1 pounds.
- Diet: Half a can of Friskies Pate AM, 1/4 cup of dry food NN, and the other half of the pate PM. Eating has improved with pate; eating is slower with dry food. No breakfast given on the morning of the visit.
- Px underwent oral surgery today. Teeth 106, 107, & 108 were extracted.

Abnormal PE/Chem/CBC/UA Results: PE: Eyes: OD: Third eyelid elevation, enophthalmos, ptosis, decreased palpebral reflex, PLR present but weak direct response, optic nerve appears abnormal. OS: PLR present, decreased with direct light, optic nerve appears normal. Ears: AU: Healing scab on pinna Oral: Tooth on upper right side appears problematic; CV: Grade II/VI heart murmur present. Musculo: Muscle loss to head. Head appears sunken. Nervous System: Right-sided ptosis with elevation of the third eyelid, decreased palpebral reflex on the right, diminished blink response on right side, decreased direct pupillary light response in the left eye, right globe appears sunken; evidence of Horner's syndrome. CBC: Eosinophils 0.16K/ $\mu$ L Chem: Glucose 205 mg/dL, Phosphorus 3.0 mg/dL, Potassium 3.4 mol/L IOP: OS 14 mmHg; OD 23 mmHg

## COMPUTED TOMOGRAPHY OF THE SKULL, THORAX AND ABDOMEN

A high resolution pre- and post-contrast CT study of the skull and abdomen and a plain CT study of the thorax is provided for review.

## COMPUTED TOMOGRAPHIC FINDINGS

### Skull

Triadan 401 is absent.

The alveolar process of the right maxillary bone, level with triadan 106 to 109 and the base of the right zygomatic bone present permeative osteolysis. A uniform soft tissue attenuating and heterogeneous contrast enhancing, ill-defined soft tissue is centered on the affected osseous structures – extending in the labial tissue up to the level of triadan 104. The right vena ophthalmica externa ventralis presents an intraluminal filling defect.

The right extraocular muscles are swollen. The region of the right trigeminal nerve is prominent.

The volume of the right masticatory muscle is moderately decreased. The right pterygoid muscles present diffuse increased contrast enhancement.

The nasal cavity presents the expected aerated spaces between thin & even conchae and turbinates with smooth mucosal lining.

Both temporomandibular joints present congruent joint spaces with even subchondral bone surfaces and are considered within normal limits.



## PATIENT

Nolan Ferguson

## SPECIES

Feline

## BREED

Domestic Shorthair

## SEX

Male Neutered

## AGE

15Y, 5M, 3D

## WEIGHT

11.10lbs

## INTERPRETED BY

Sebastian Schaub, DVM  
Dr. med. vet.  
DipECVDI

## IMAGING PERFORMED BY

Joseph D'Abbraccio,  
DVM

## HOSPITAL NAME

Catskill Veterinary  
Services, PLLC

## REFERRING VET

Joseph D'Abbraccio,  
DVM

## INVOICE

73387

## DATE

1-20-26

Both tympanic bullae are aerated, the mucosal lining is not seen, the bony wall is smooth and thin. The external ear canals are within normal limits.

Post contrast administration in the right dorsal aspect of the cranial fossa – level with the transition between the right frontal & parietal lobe, a to the calvarium broad based, strong contrast enhancing, convex shaped mass is bulging into the cranial fossa; measuring 7 x 4 x 10 mm.

The submandibular and medial retropharyngeal lymph nodes are small and elongated with a normal short-to-long-axis-ratio is < 0.5, the attenuation and contrast enhancement pattern is uniform.

### Thorax

Along the thoracic spine, multifocal mild spondylosis formation is seen.

The sternal, cranial mediastinal and tracheobronchial lymph nodes are small elongated with a normal short-to-long-axis-ratio is < 0.5, the attenuation pattern is uniform.

The cardiovascular structures including the pulmonary vasculature are within normal limits.

The bronchial tree presents with regular branching and tapers uniformly towards the periphery as expected, the bronchial walls are thin and smooth. The bronchus-to-artery ratio is within normal limits.

The lung parenchyma presents the expected architecture and attenuation behavior.

Small incidental gas pockets are seen within the esophageal lumen; there is no evidence of abnormal dilation.

### Abdomen

The serosal fat presents normal attenuation behavior. There is no evidence of peritoneal effusion or peritonitis.

Both kidneys present within normal limits for size, shape and organ architecture. After contrast administration, a bilaterally symmetric and uniform nephro- and pyelogram is noted.

The adrenal glands are within normal limits for size, shape and organ architecture.

The spleen presents with normal shape, even surface, uniformly attenuating parenchyma and homogeneous contrast enhancement, unremarkable.

The liver is normal in size and shape. Multifocal throughout the hepatic parenchyma, well-defined, irregular roundish parenchymal filling defects are seen; measuring < 5 mm in diameter.

The pancreas is evenly contoured; the pancreatic parenchyma is homogeneous and presents uniform contrast enhancement.

The position, delineation, wall and content of the gastrointestinal tract are considered within normal limits throughout.

The periarticular bones of both coxofemoral joints present mild osteophyte new bone formation.

## COMPUTED TOMOGRAPHIC DIAGNOSIS

- Polyostotic aggressive osteolytic lesion right maxillary bone and right zygomatic bone with associated soft tissue mass – presenting an invasive growth into the local soft tissue structures
- Swelling right extraocular muscles
- Prominent right trigeminal nerve
- Thrombus in right vena ophthalmica externa ventralis



## PATIENT

Nolan Ferguson

## SPECIES

Feline

## BREED

Domestic Shorthair

## SEX

Male Neutered

## AGE

15Y, 5M, 3D

## WEIGHT

11.10lbs

## INTERPRETED BY

Sebastian Schaub, DVM  
Dr. med. vet.  
DipECVDI

## IMAGING PERFORMED BY

Joseph D'Abbraccio,  
DVM

## HOSPITAL NAME

Catskill Veterinary  
Services, PLLC

## REFERRING VET

Joseph D'Abbraccio,  
DVM

## INVOICE

73387

## DATE

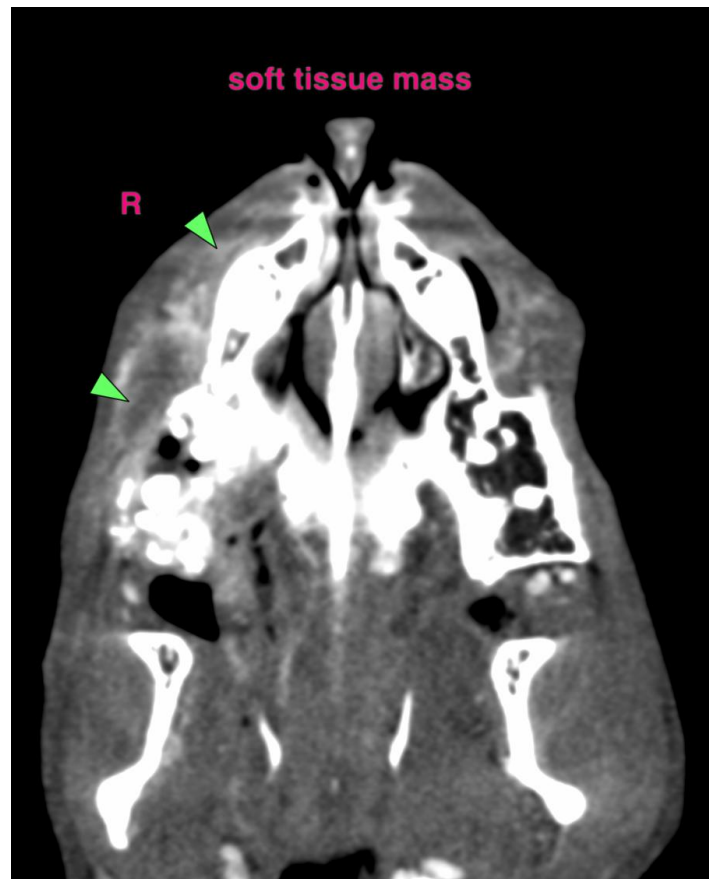
1-20-26

- Neurogenic atrophy right masticatory muscles
- Intracranial extraaxial contrast enhancing mass right dorsal aspect of the cranial fossa
- Multiple simple hepatic cysts
- Absent triadan 401
- Mild osteoarthritis coxofemoral joints
- Spondylosis deformans
- No evidence of pulmonary metastatic disease

## INTERPRETATION OF THE FINDINGS & FURTHER RECOMMENDATIONS

The local aggressive soft tissue mass centered on the right maxillary bone is consistent with primary soft tissue neoplasia – such as squamous cell carcinoma, fibrosarcoma, melanoma, other. FNA sampling /biopsy can be performed for specification. The swelling along the course of the right trigeminal nerve and the extraocular muscles is highly suggestive for local extent of the maxillary mass along the respective anatomical structures. The findings are a likely explanation for the presenting clinical signs.

The appreciated intracranial extraaxial mass is considered as a second entity – such as meningioma – meningeal metastasis is a potential.





## PATIENT

Nolan Ferguson

## SPECIES

Feline

## BREED

Domestic Shorthair

## SEX

Male Neutered

## AGE

15Y, 5M, 3D

## WEIGHT

11.10lbs

## INTERPRETED BY

Sebastian Schaub, DVM  
Dr. med. vet.  
DipECVDI

## IMAGING PERFORMED BY

Joseph D'Abbraccio,  
DVM

## HOSPITAL NAME

Catskill Veterinary  
Services, PLLC

## REFERRING VET

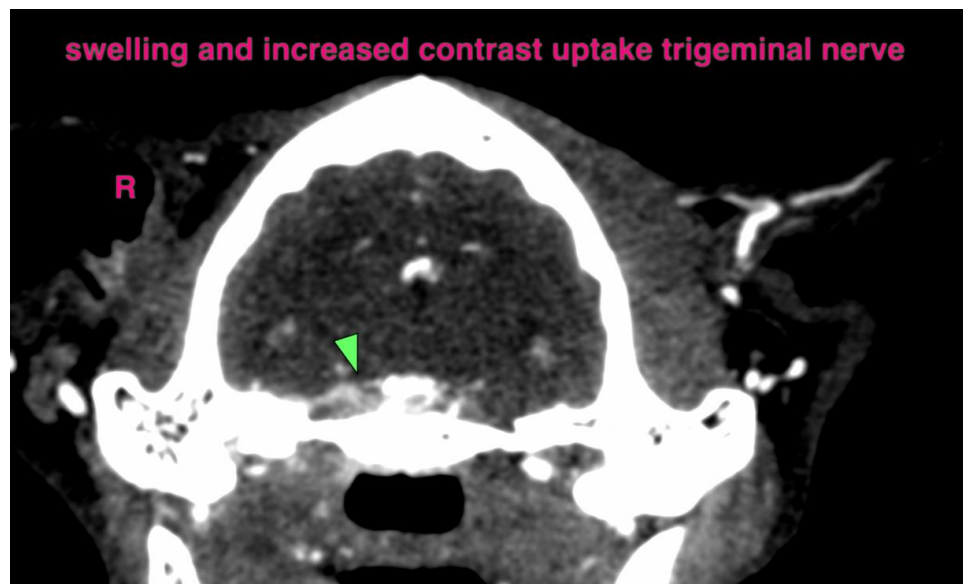
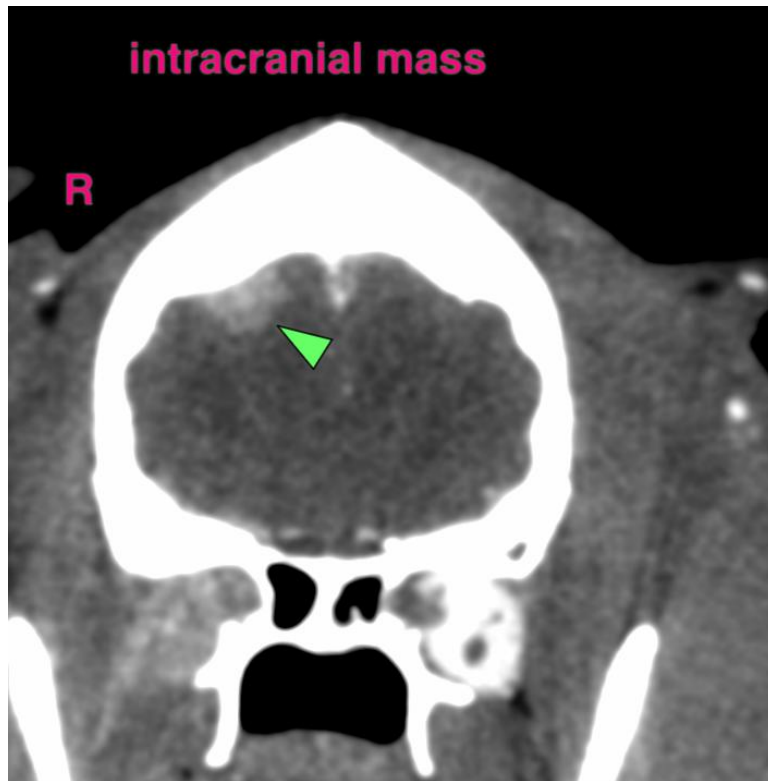
Joseph D'Abbraccio,  
DVM

## INVOICE

73387

## DATE

1-20-26





## PATIENT

Nolan Ferguson

## SPECIES

Feline

## BREED

Domestic Shorthair

## SEX

Male Neutered

## AGE

15Y, 5M, 3D

## WEIGHT

11.10lbs

## INTERPRETED BY

Sebastian Schaub, DVM  
Dr. med. vet.  
DipECVDI

## IMAGING PERFORMED BY

Joseph D'Abbraccio,  
DVM

## HOSPITAL NAME

Catskill Veterinary  
Services, PLLC

## REFERRING VET

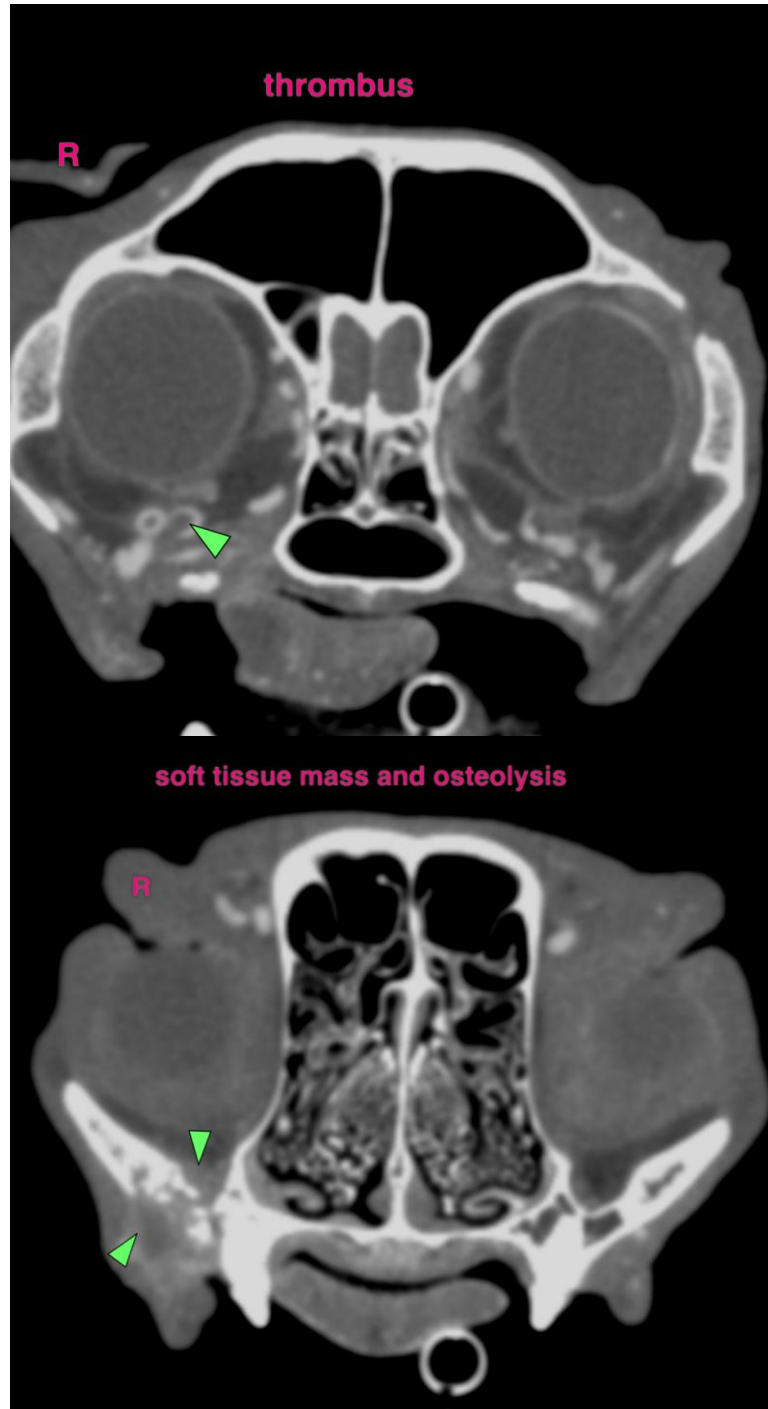
Joseph D'Abbraccio,  
DVM

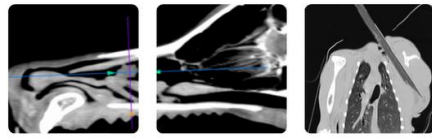
## INVOICE

73387

## DATE

1-20-26





## PATIENT

Nolan Ferguson

## SPECIES

Feline

## BREED

Domestic Shorthair

## SEX

Male Neutered

## AGE

15Y, 5M, 3D

## WEIGHT

11.10lbs

## INTERPRETED BY

Sebastian Schaub, DVM  
Dr. med. vet.  
DipECVDI

## IMAGING PERFORMED BY

Joseph D'Abbraccio,  
DVM

## HOSPITAL NAME

Catskill Veterinary  
Services, PLLC

## REFERRING VET

Joseph D'Abbraccio,  
DVM

## INVOICE

73387

## DATE

1-20-26

The information and recommendations provided are based on the images presented by the referring veterinarian/sonographer. No evaluation can be communicated regarding pathology that was not visible in the image/video clips provided.

Thank you for this referral. If the clinical or image interpretation does not parallel your findings or if I can be of any further assistance please contact me.

**Sebastian Schaub**, Sebastian Schaub, DVM, Dr. med. vet. DipECVDI  
[info@sonopath.com](mailto:info@sonopath.com)