



PATIENT

Luna Zarate

SPECIES

Feline

BREED

DSH

SEX

FS

AGE

8

WEIGHT

14.4lbs

INTERPRETED BY

Sebastian Schaub, DVM
Dr. med. vet.
DipECVDP

IMAGING PERFORMED BY

Arch Gordon

HOSPITAL NAME

Coral Ridge Animal
Hospital

REFERRING VET

Arch Gordon

INVOICE

73389

DATE

1-20-26

PRESENTING CLINICAL SIGNS

History:

- O noted congestion /breathing more heavily
- mild pharyngitis noted - upper respiratory congestion
- febrile at 103.1
- mild dry rales - very slight
- pro BNP pending

Abnormal PE/Chem/CBC/UA Results: CBC and Vet Screen in 9/2025 was normal thyroid not measured

RADIOGRAPHIC STUDY OF THE THORAX

Radiographs of the thorax in two orthogonal image planes are provided for review.

RADIOGRAPHIC FINDINGS

The body condition score is 8-9/9.

The surrounding bony structures are within normal limits.

The extrathoracic soft tissues present homogeneous without abnormalities.

The mediastinum is significantly widened by fat.

The heart is of normal size and shape; there is no evidence of cardiac chamber or vascular enlargement. The pulmonary vasculature is within normal limits.

The trachea is normal in diameter and presents the anticipated course. The luminal outline of the trachea is smooth.

The bronchial tree presents with thin walls and tapers uniformly towards the periphery as expected.

The lung parenchyma presents the expected architecture and generalized ground glass opacity; the intrapulmonary vascular branching is seen up to the third order lung vessels.

The diaphragm is well delineated with even surface and the expected mild cranial bulging of the diaphragmatic cupola.

RADIOGRAPHIC DIAGNOSIS

- Obesity

INTERPRETATION OF THE FINDINGS & FURTHER RECOMMENDATIONS

The radiographic study presents no abnormalities of the lower airways, but the obesity. The latter is explaining the generalized ground glass opacity of the lung parenchyma, due to summation and overall decreased pulmonary volume.



PATIENT

Luna Zarate

SPECIES

Feline

BREED

DSH

SEX

FS

AGE

8

WEIGHT

14.4lbs

INTERPRETED BY

Sebastian Schaub, DVM
Dr. med. vet.
DipECVDI

IMAGING PERFORMED BY

Arch Gordon

HOSPITAL NAME

Coral Ridge Animal
Hospital

REFERRING VET

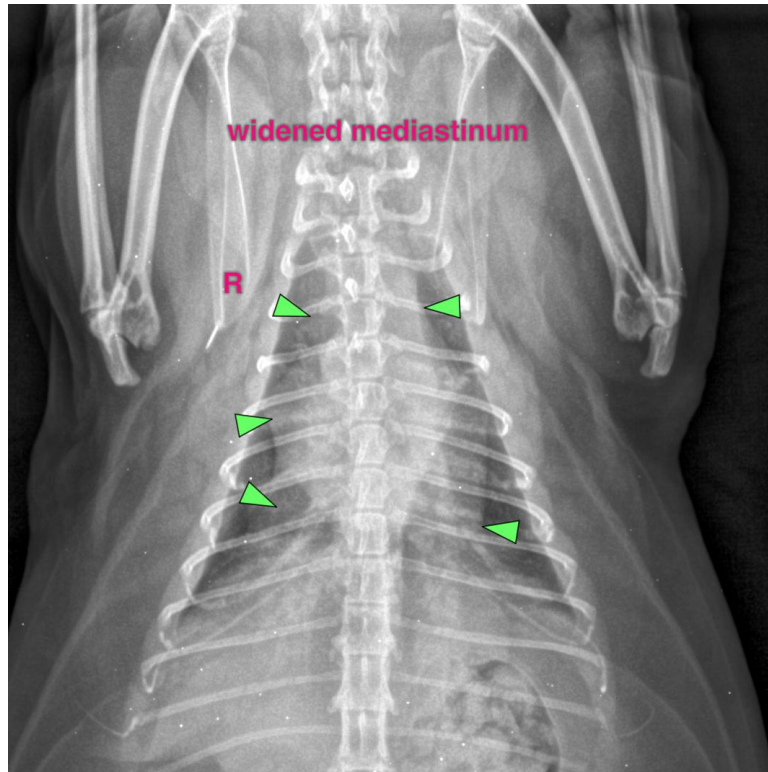
Arch Gordon

INVOICE

73389

DATE

1-20-26



The information and recommendations provided are based on the images presented by the referring veterinarian/sonographer. No evaluation can be communicated regarding pathology that was not visible in the image/video clips provided.

Thank you for this referral. If the clinical or image interpretation does not parallel your findings or if I can be of any further assistance please contact me.

Sebastian Schaub, Sebastian Schaub, DVM, Dr. med. vet. DipECVDI

info@sonopath.com